



the Child Dental Patient with

Fragile X syndrome - clinical case -



Bambino Gesù
OSPEDALE PEDIATRICO

FS, f, age at first visit: 8 y 4 m

General dg: X fragile syndrome

History of cleft palate: Furlow's palatoplasty surgical procedure at age 5 y 9 m (2016)

Intraoral examination:

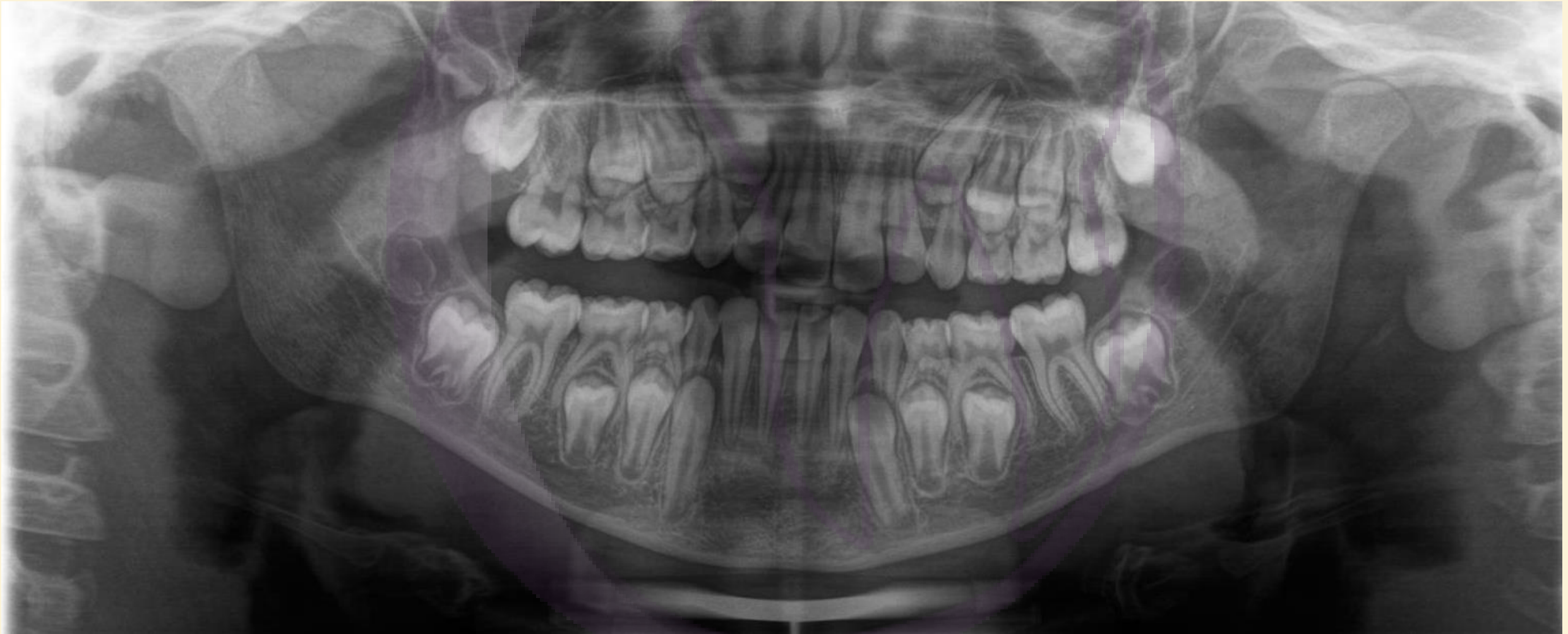- Mixed dentition
- Absence of caries
- Diffuse dental plaque
- Contraction of the maxilla with unilateral left crossbite

- **Reason for seeking treatment** → contraction of the maxilla resulting in unilateral left crossbite
- Difficulty in gaining the patient's confidence and cooperation in the first stages of the treatment. The patient refused to enter the room and undergo dental visits and showed various episodes of nervousness.
- The first appointments were dedicated to the familiarization with the dental chair and the clinic environment and trying to gain the patient's confidence in order to start with the treatments.
- During the first appointments Tell-Show-Do methods were adopted and with time and patience she started to trust the staff and our clinic environment until we could proceed with her first dental cleaning and with the beginning of the orthodontic treatment.

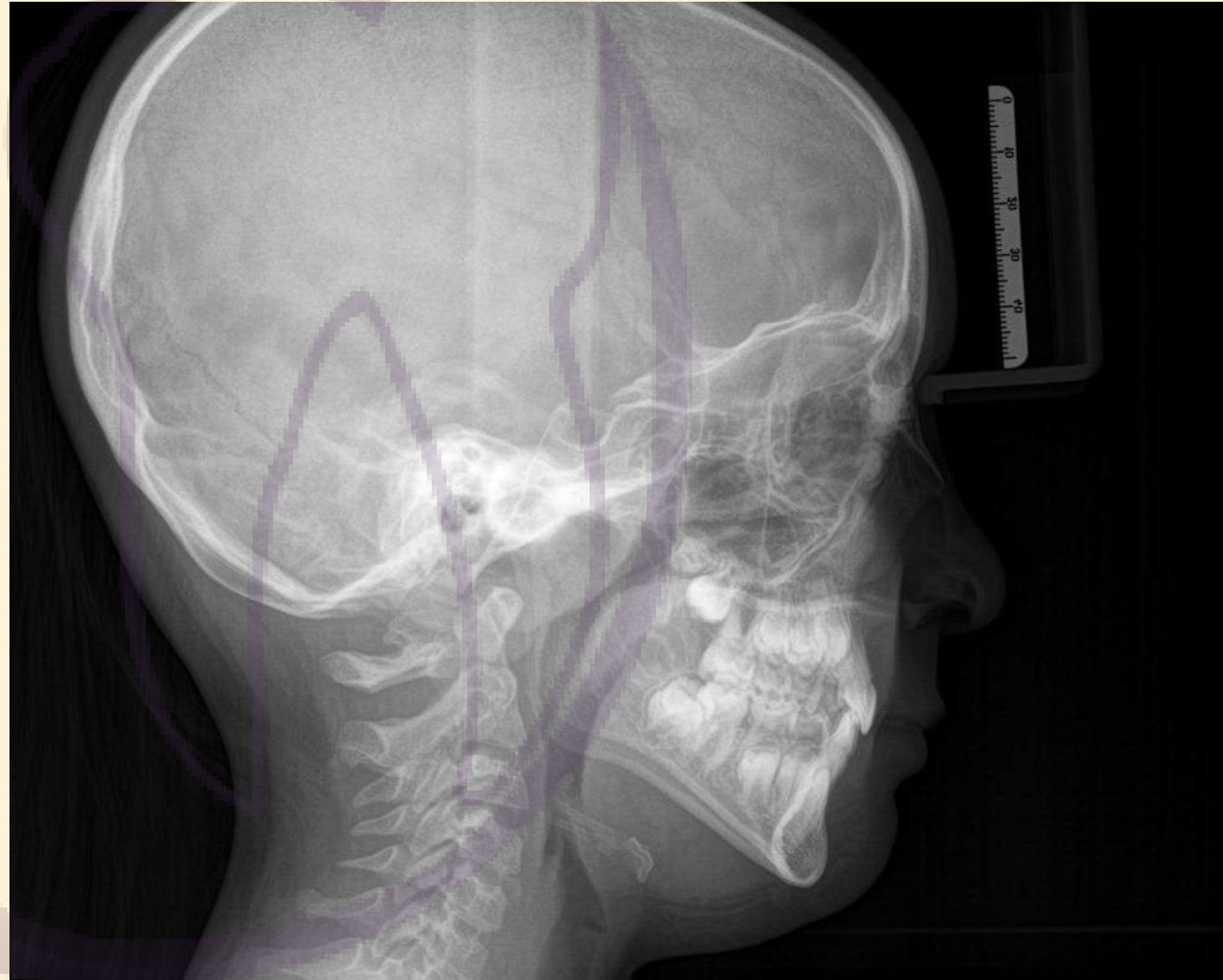
Treatment

- A professional dental cleaning was performed as the first treatment. This allowed the patient to familiarize with the dental chair and with the dental equipment.
- Orthodontic treatment : rapid maxillary expansion (REM) device for 1 year (depending on the patient's collaboration).

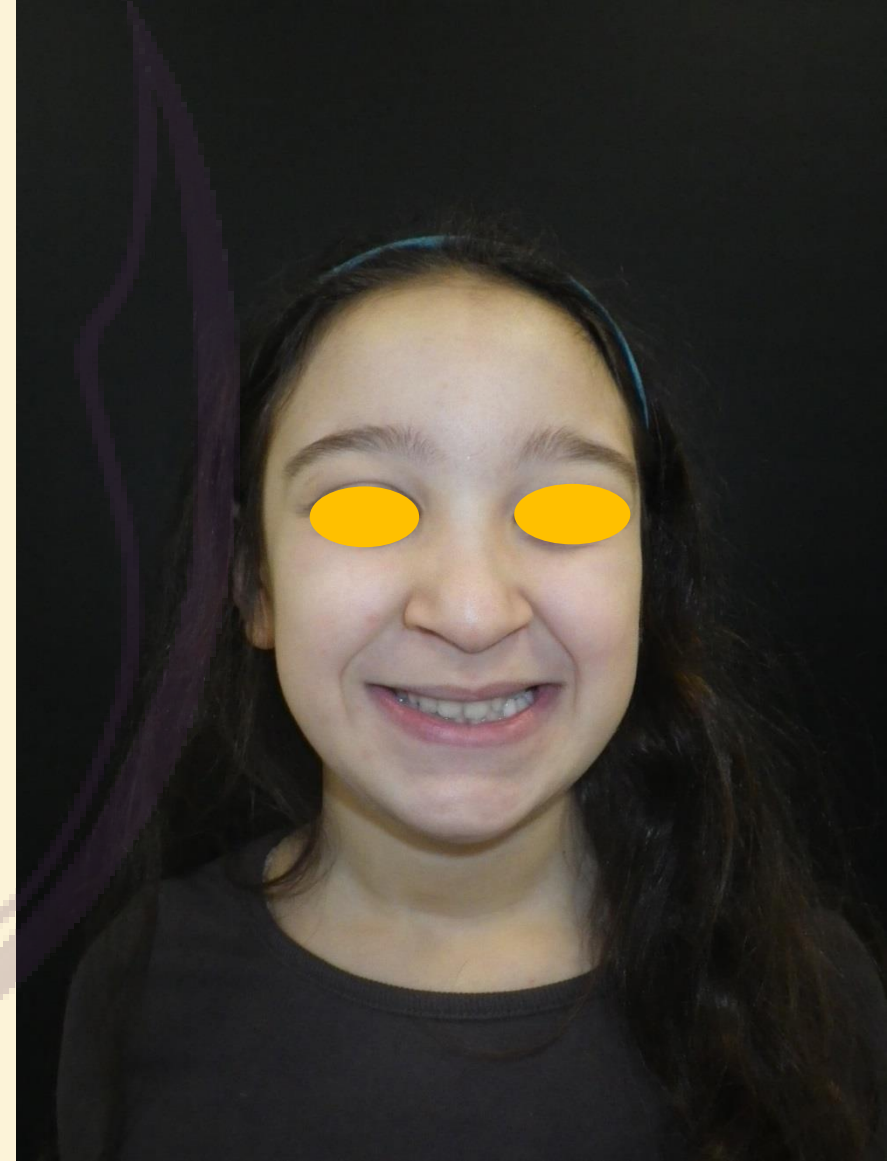Panoramic x-ray at age 8 y 4 m



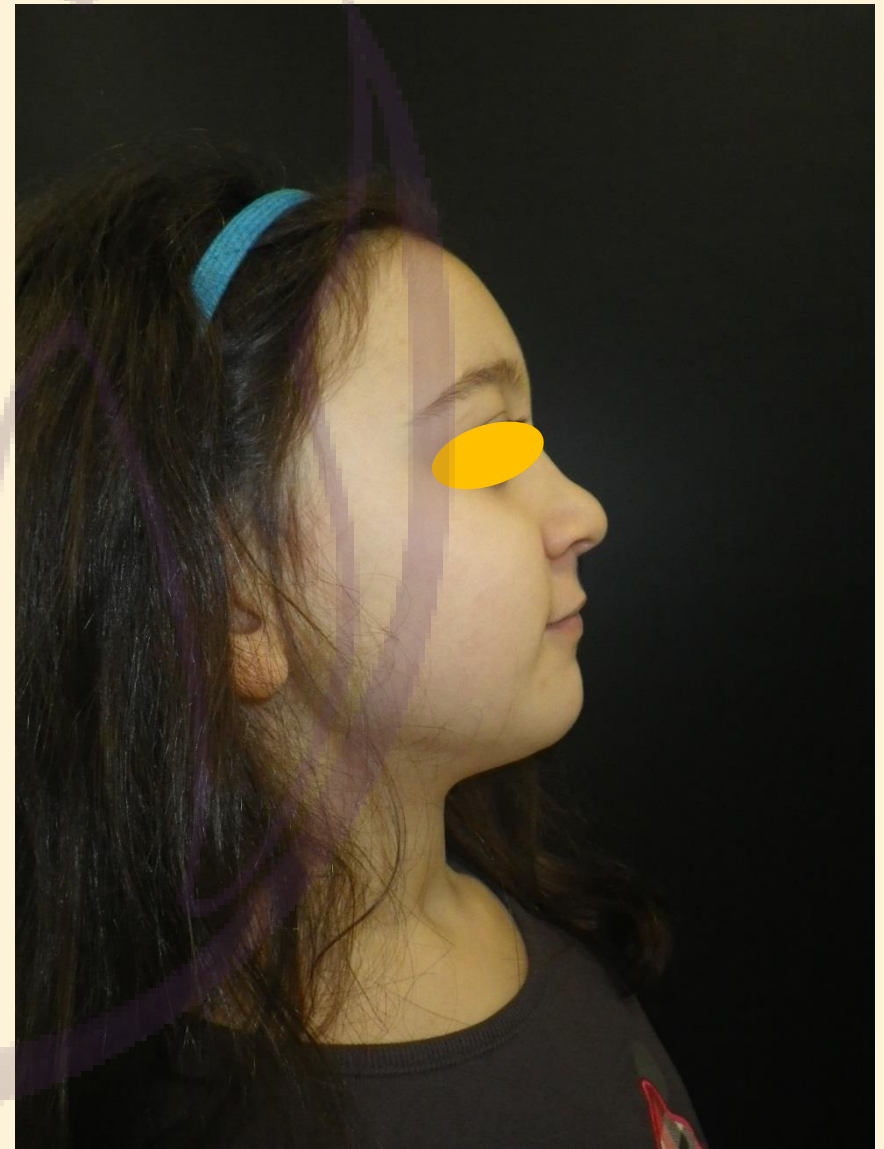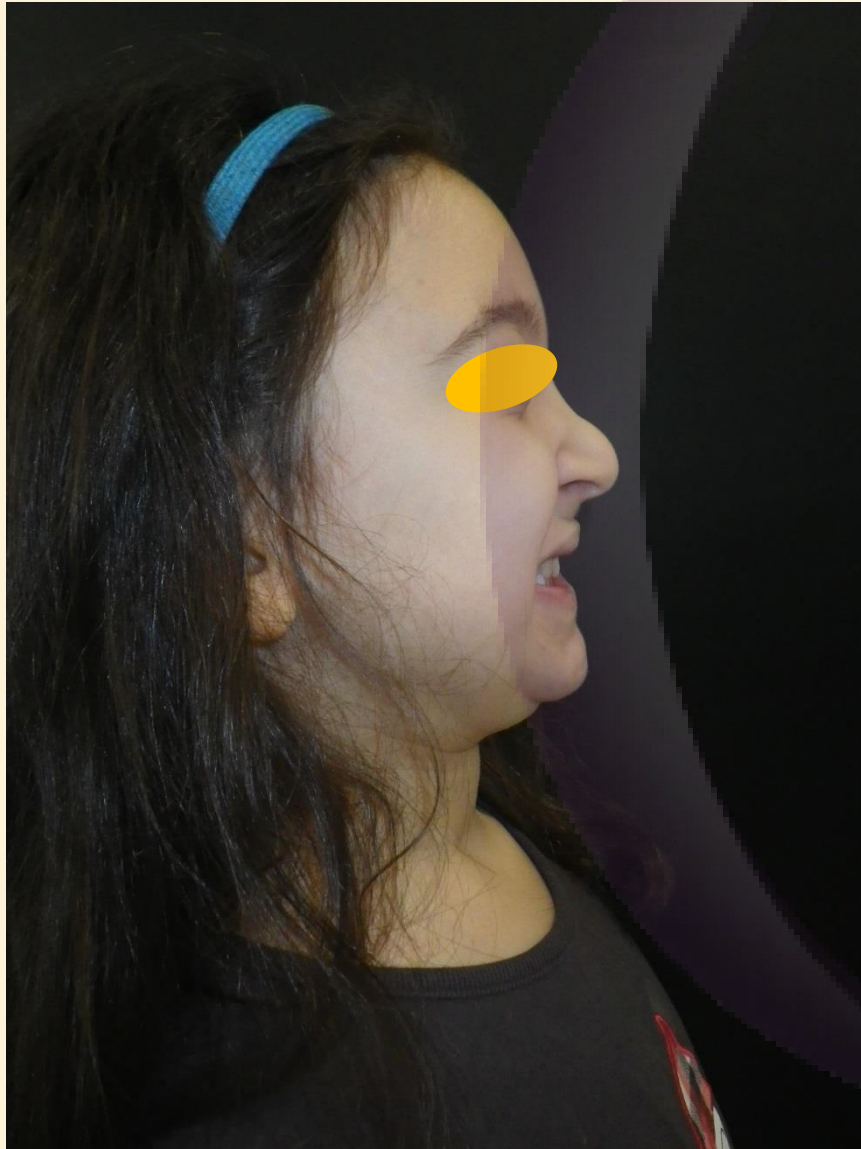Latero-lateral teleradiography age 8 y 4 m



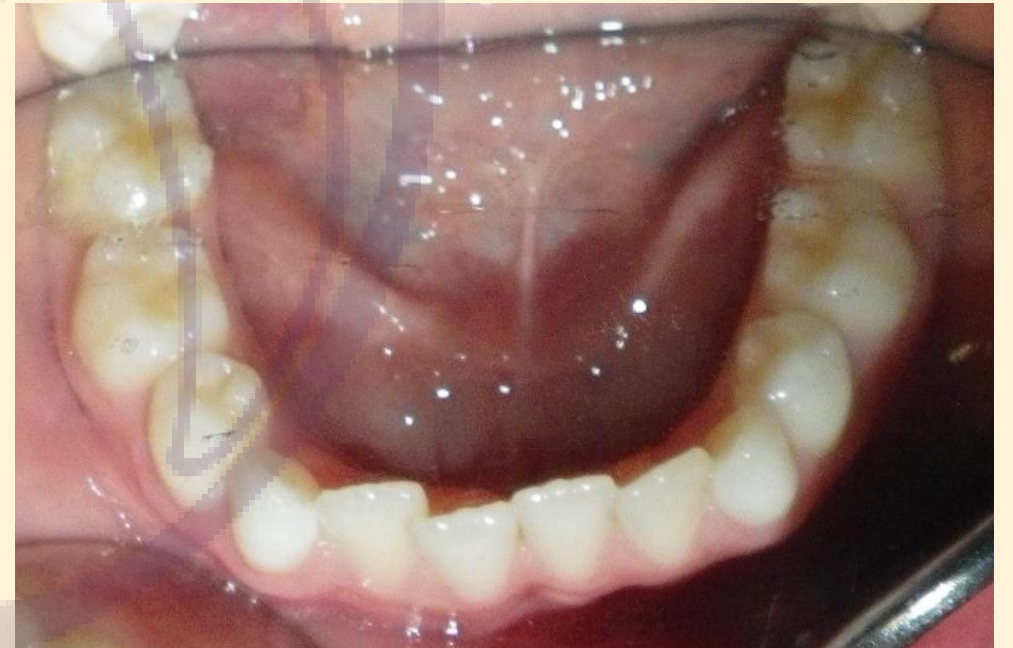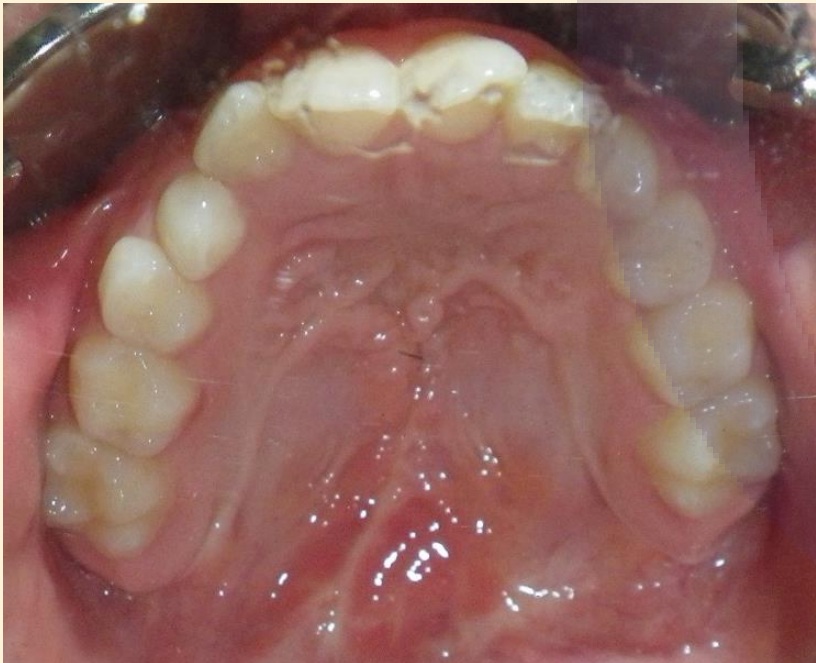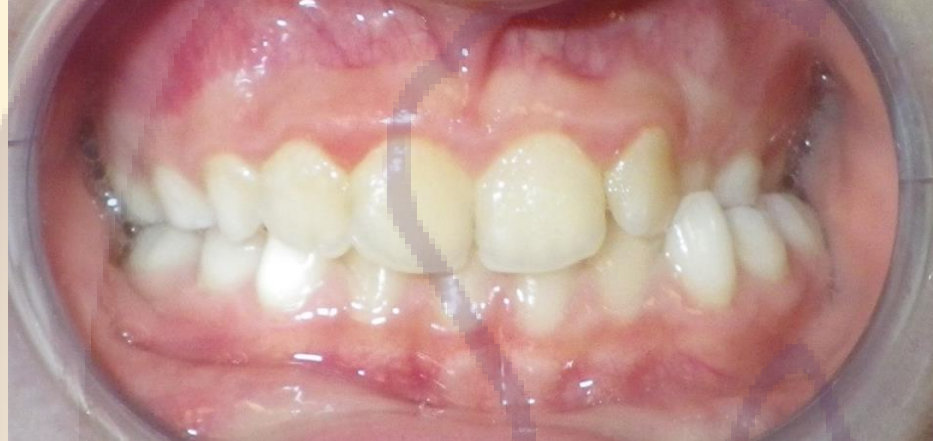Extraoral pictures for the orthodontic check up :
age 8 y 7 m



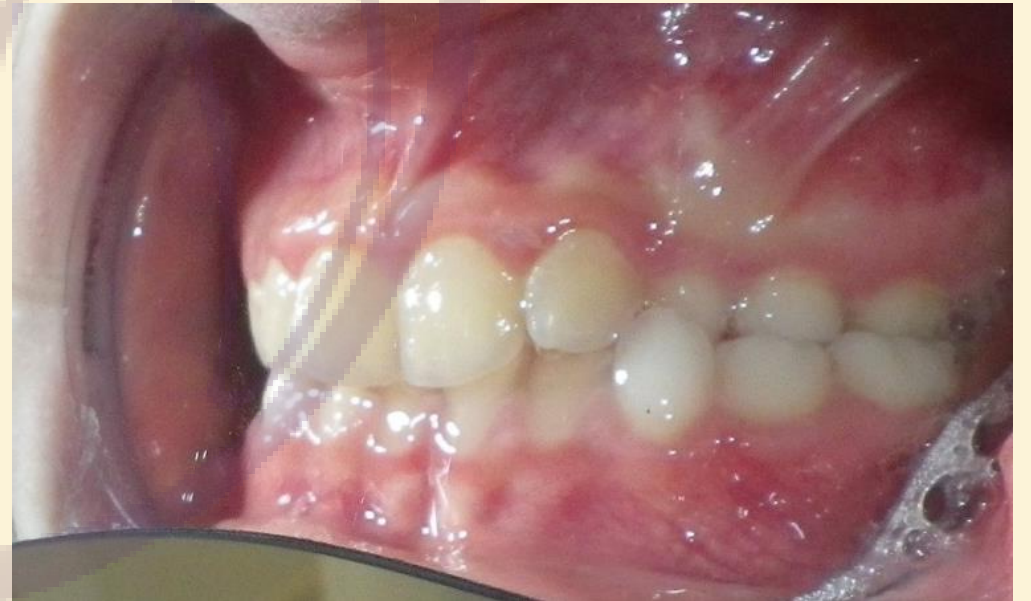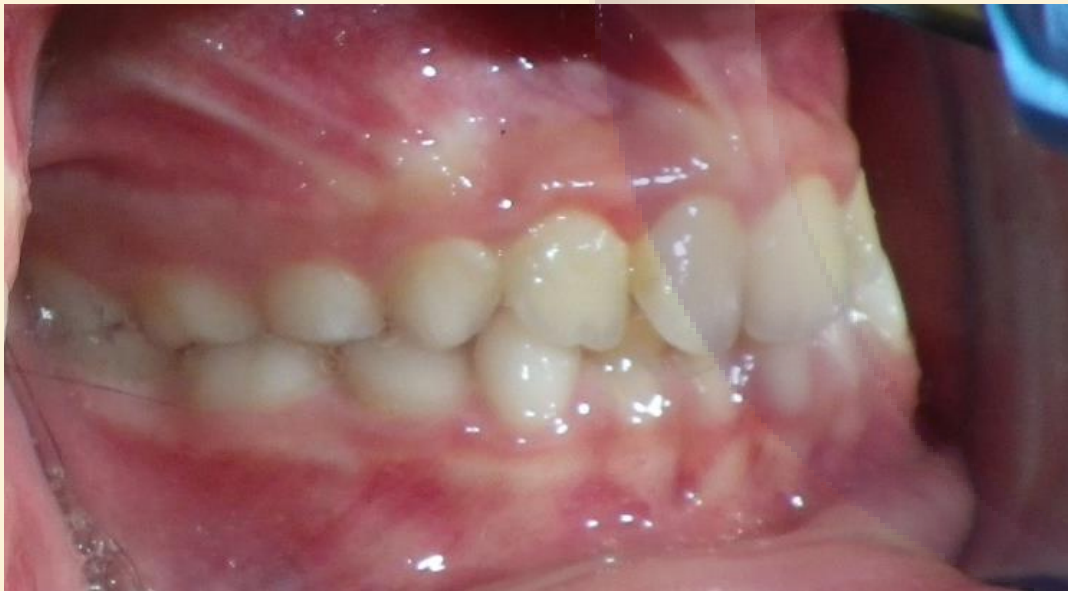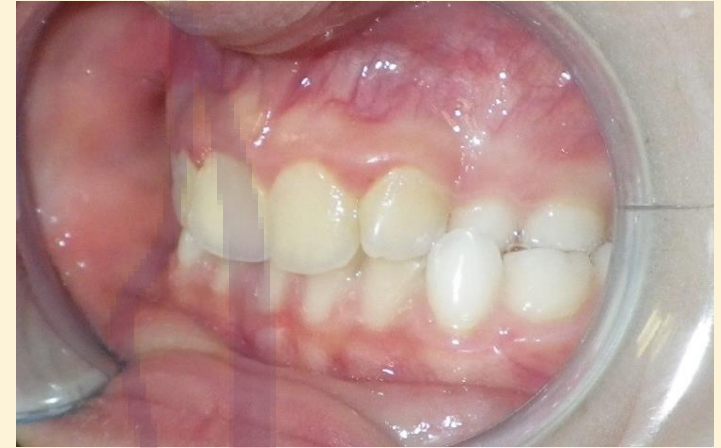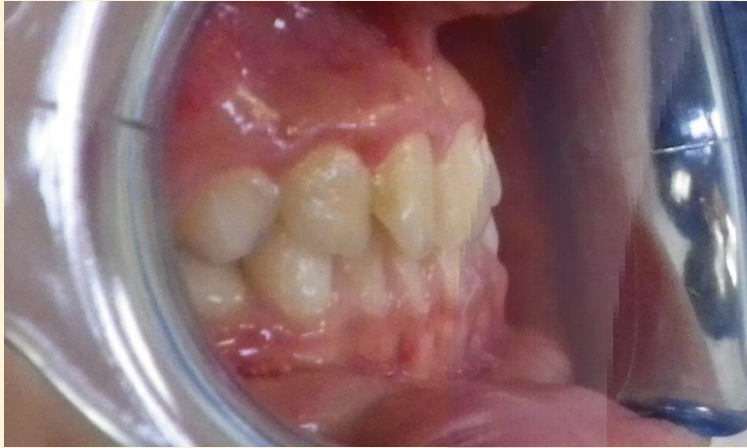Extraoral pictures for the orthodontic check up :
8 years and 7 months old



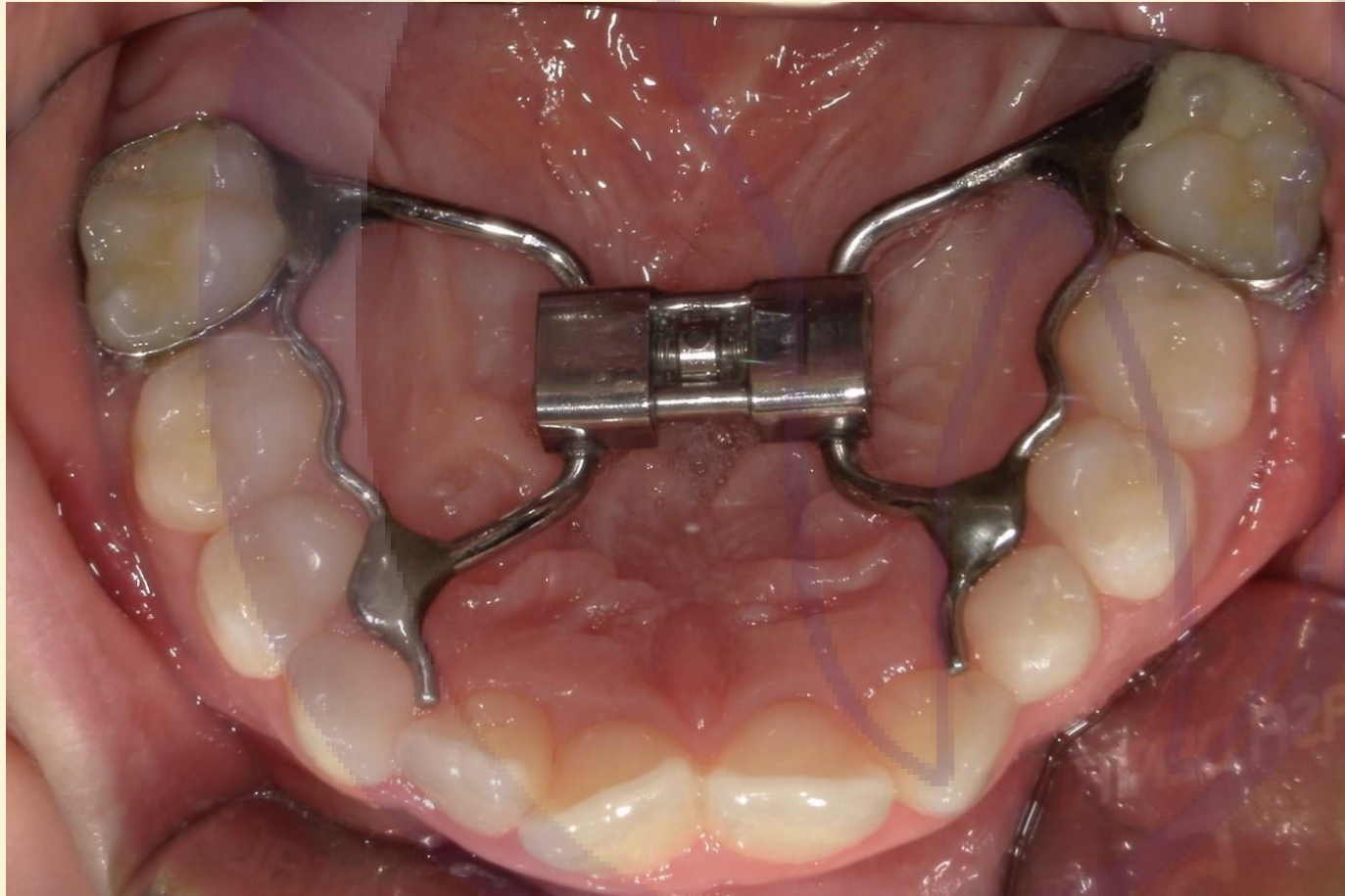
Intraoral pictures for the orthodontic check up :
8 years and 7 months old



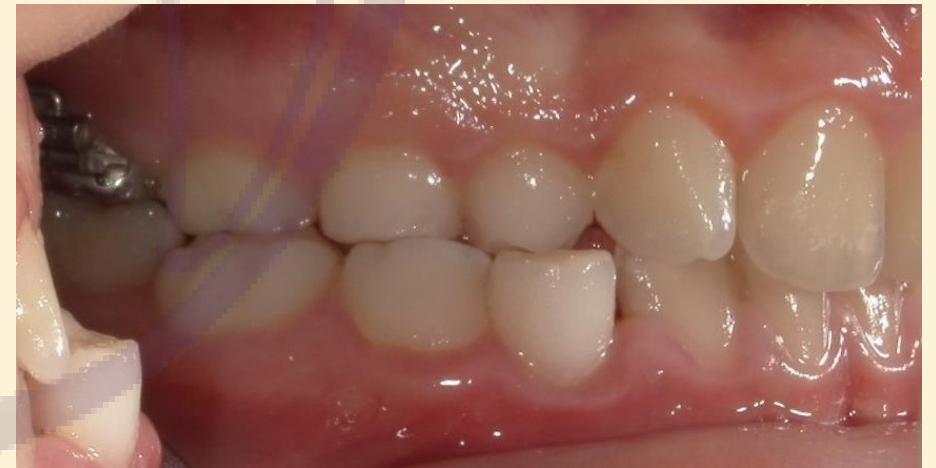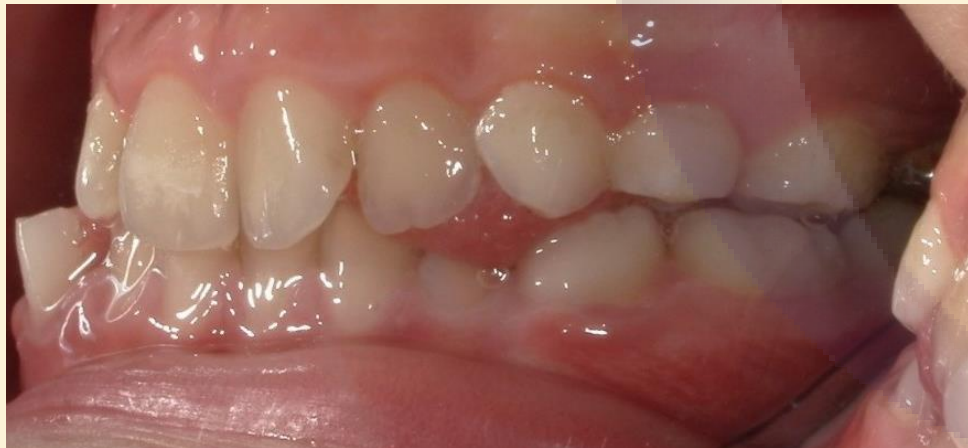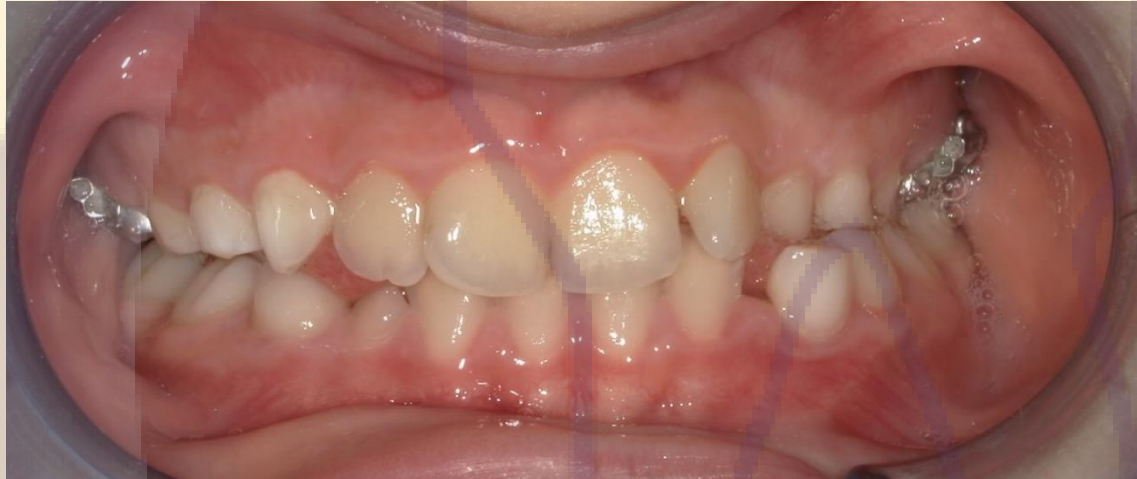Intraoral pictures for the orthodontic check up :
8 years and 7 months old

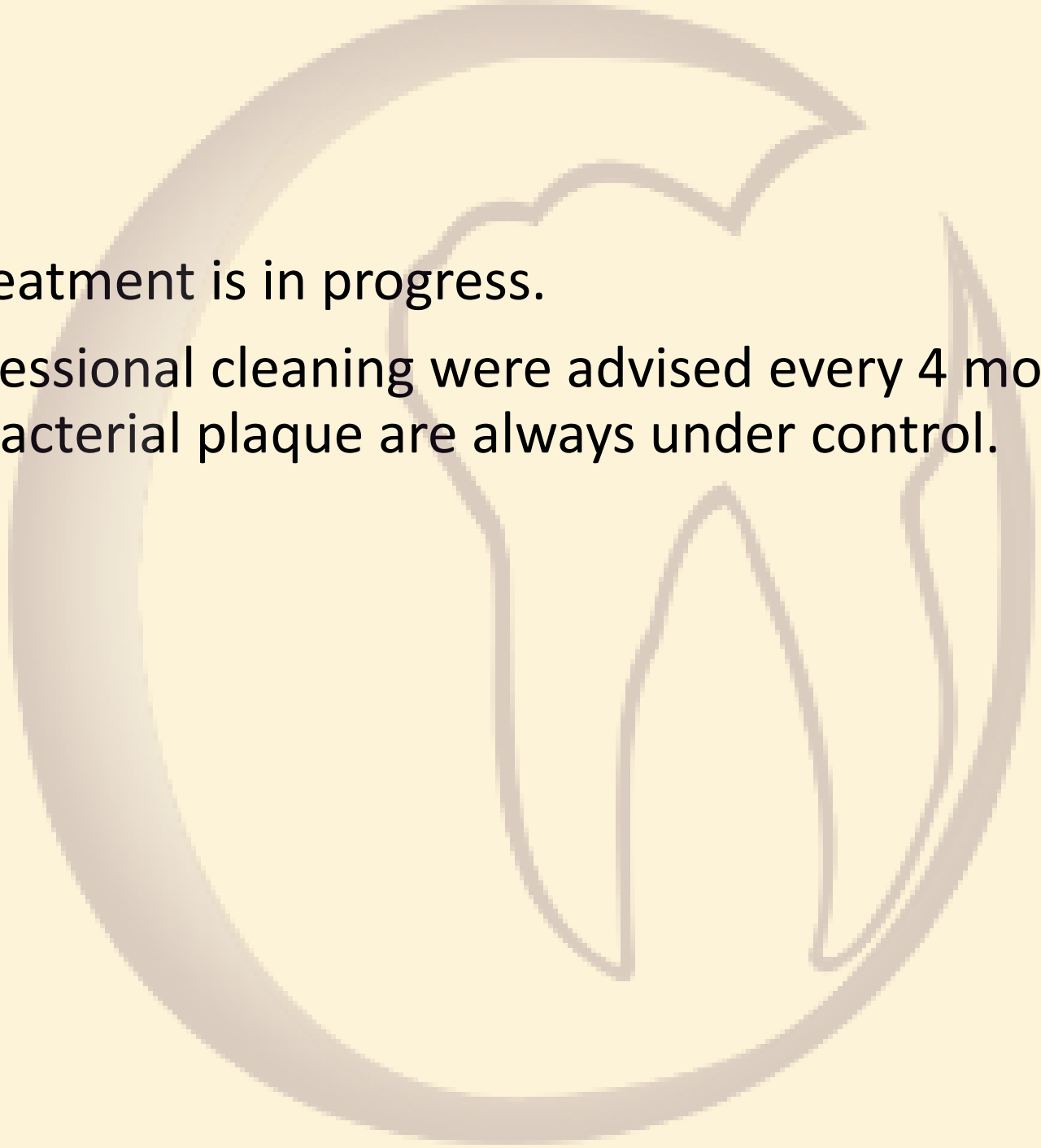


Intraoral picture of the rapid maxillary expansion device :
9 years and 5 months old



Intraoral pictures with the REM device (age 9 y 5 m)



- 
- Orthodontic treatment is in progress.
 - Recalls for professional cleaning were advised every 4 months so that gingivitis and bacterial plaque are always under control.