




the Child Dental Patient with

Williams Syndrome



European Reference Network

for rare or low prevalence complex diseases

- ⚙️ **Network**
Craniofacial anomalies and ear, nose and throat disorders (ERN CRANIO)
- **Member**
Hôpitaux Universitaires de Strasbourg — France

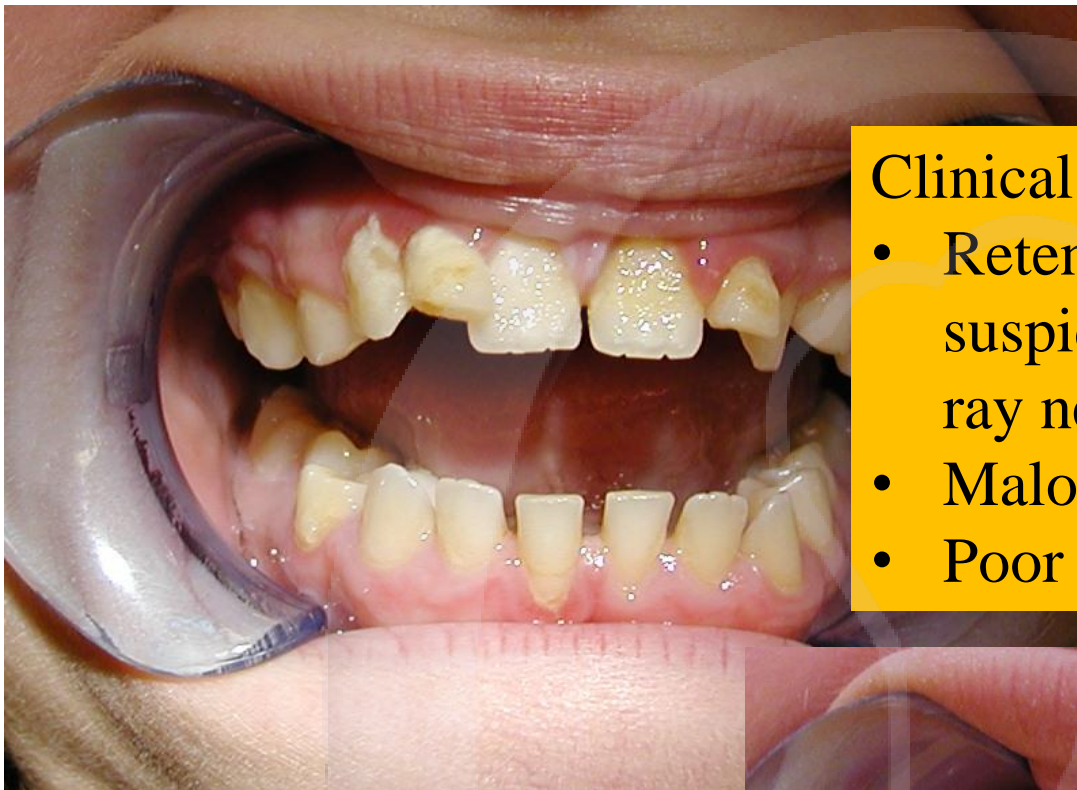General dg.: Williams-Beuren syndrome
Dental dg.: mixed dentition, with retention of deciduous teeth, microdontia, teeth agenesis



Characteristic features:

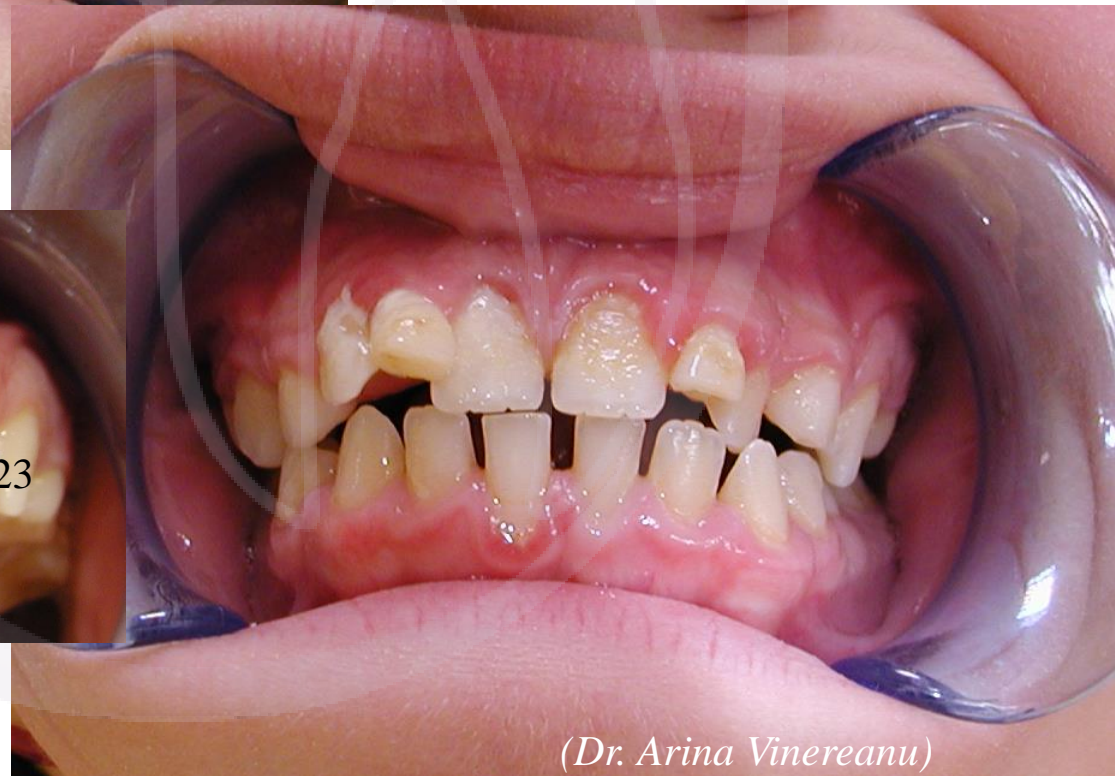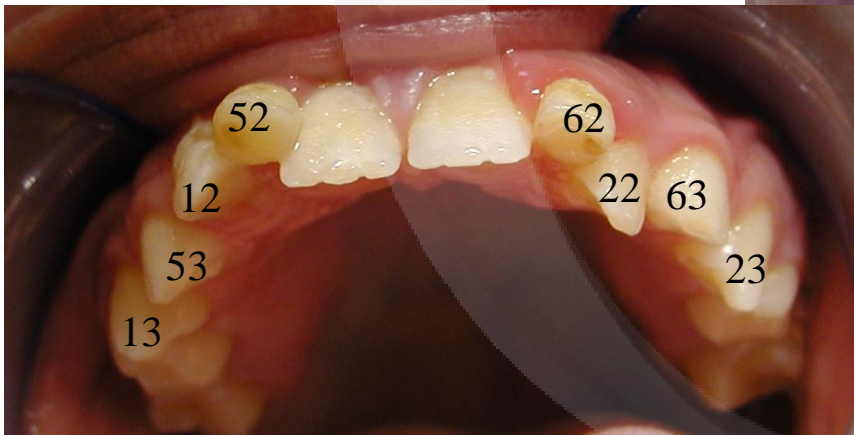
- “elfin” appearance, thick lips, saddle nose, anteverted nostrils (blue eyes)
- highly sociable, talkative

(Dr. Arina Vinereanu)

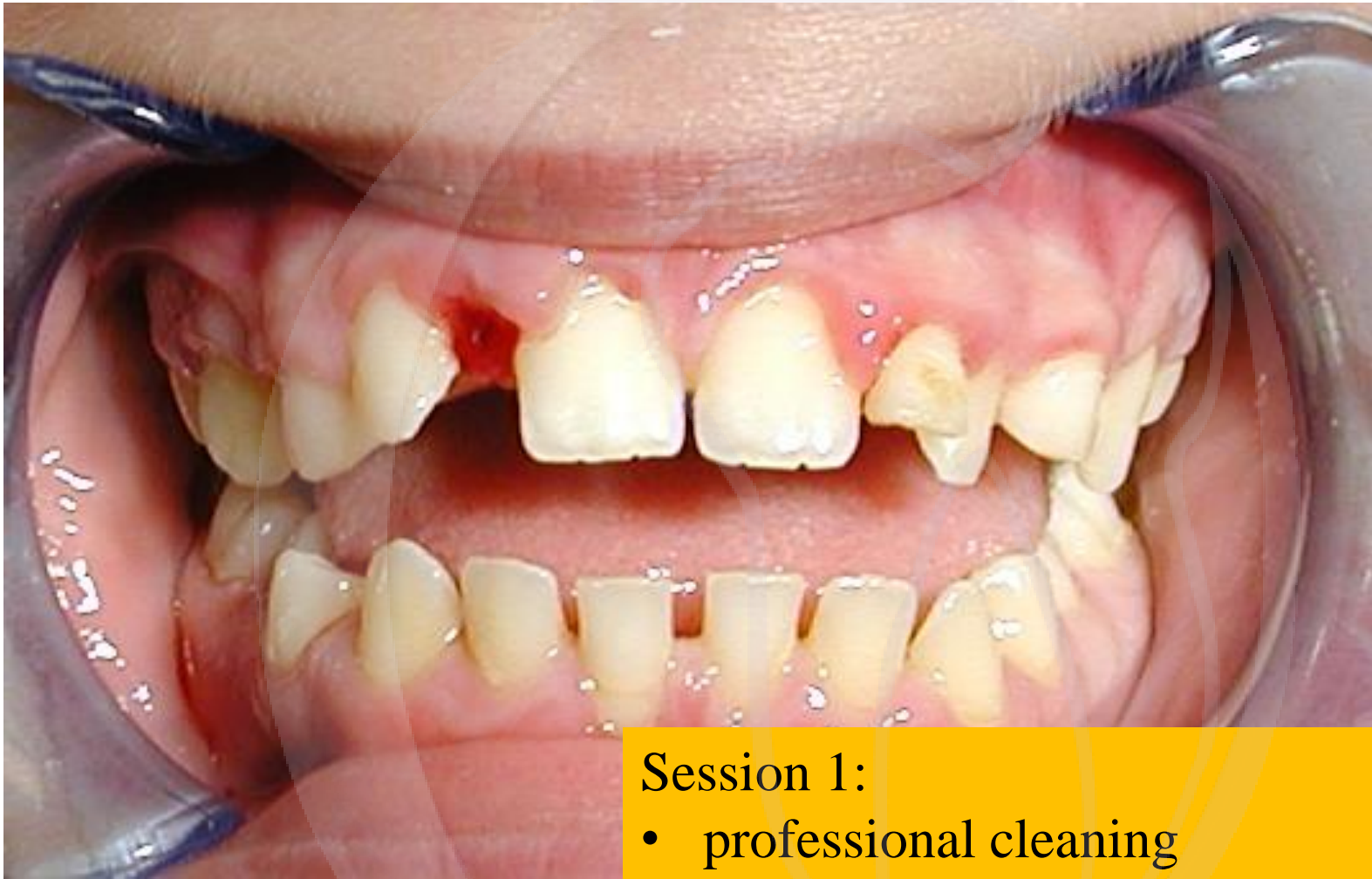

Clinical findings:

- Retention of 6 primary teeth – suspicion of multiple agenesis – X-ray needed
- Malocclusion
- Poor hygiene

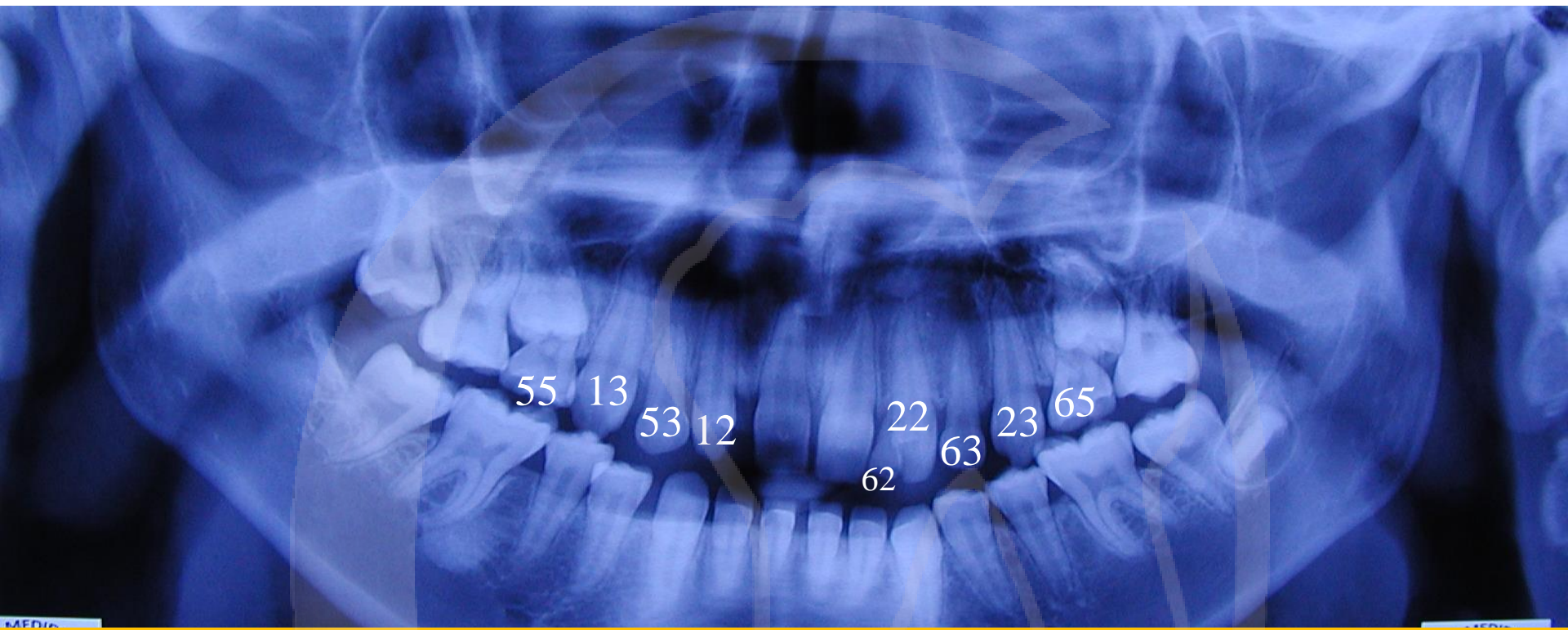


(Dr. Arina Vinereanu)



Session 1:

- professional cleaning
- extraction of 52 (topical anaesthesia)



Panoramic Xray (taken after extraction of 52) confirms agenesis (probably 14, 24).

Hypodontia and microdontia permits the upper deciduous canines to remain on the arch, while one upper premolar is missing on both sides (14/15?; 24/25?).

Extraction of 62 and 55, 65 are planned in order to make place for the existing premolars to emerge. 53, 63 shall be kept.

After extractions patient did not show for follow-ups.