



Pompe disease Or Glycogenosis type II

Dr. Angela Galeotti

Pediatric Hospital Bambino Gesù
Odontostomatology OU



Co-funded by the
Erasmus+ Programme
of the European Union





Special thanks to

Dr. Paola Festa

&

***Pediatric Hospital Bambino Gesù
Metabolic Diseases OU***



Co-funded by the
Erasmus+ Programme
of the European Union





CLINICAL CASES



Co-funded by the
Erasmus+ Programme
of the European Union





N. J., August 11th 2010

- **CLASSIC INFANTILE POMPE DISEASE**

- Diagnosed at the age of 3 months by the Metabolic Pathology OU
- Severe hypertrophic cardiomyopathy
- Hepatomegaly
- Chronic respiratory failure in therapy with non-invasive ventilation (NIV)
- Hypotonia and muscular hypotrophy
- Enzyme replacement therapy with Myozyme
- ***Oral hygiene and prophylaxis***
- ***Dental treatment of decayed teeth***
- ***Rehabilitation therapy of facio-oral-deglutition functions including exercises to improve chewing and lip competence***
- ***Orthodontic treatment with chin rest and Class III elastic splints***

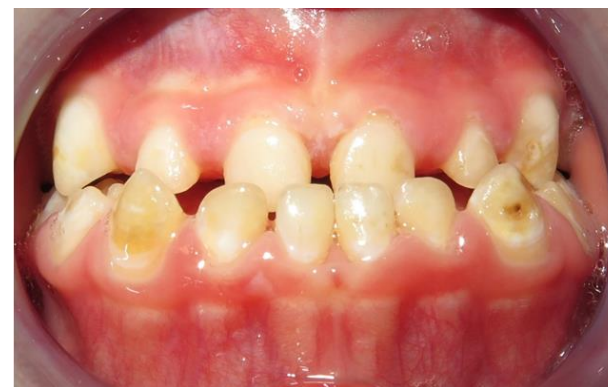
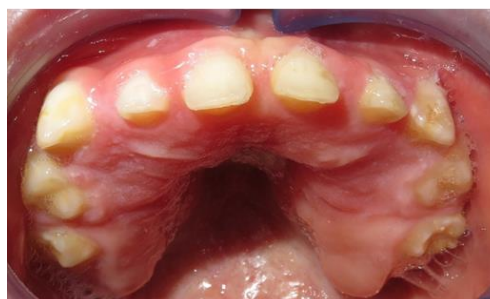
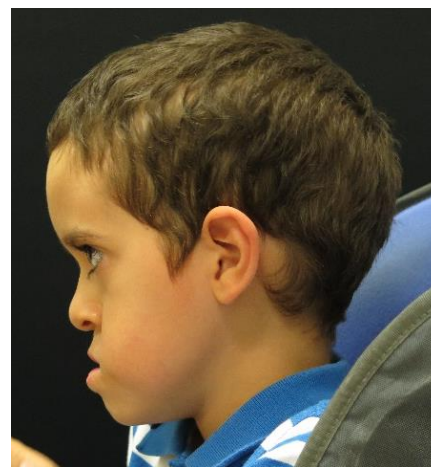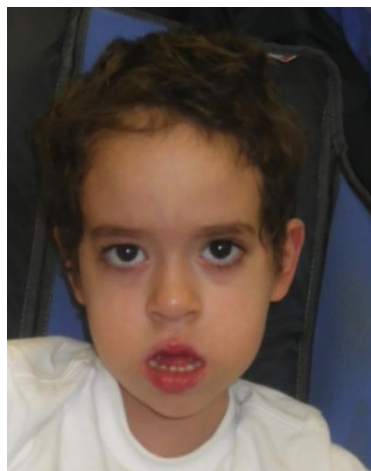Co-funded by the
Erasmus+ Programme
of the European Union



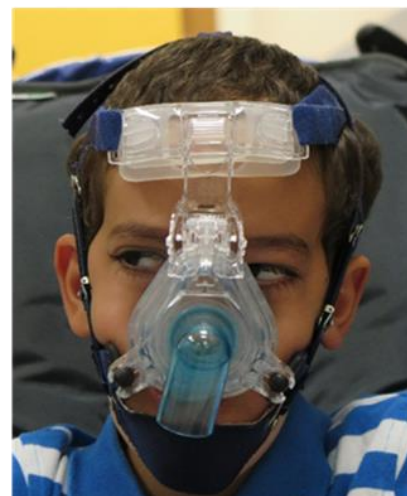
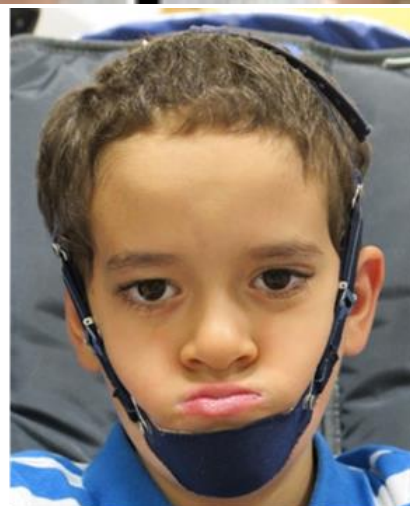
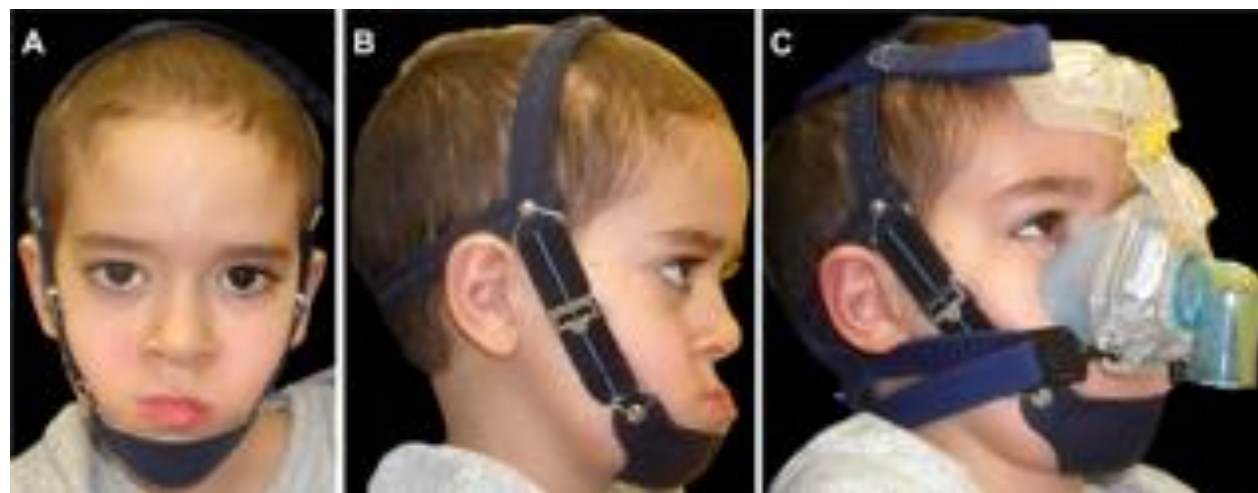N. J, 4 years old





N. J, 5 years old

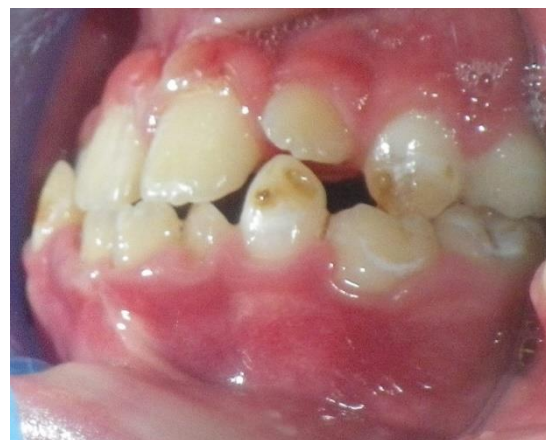
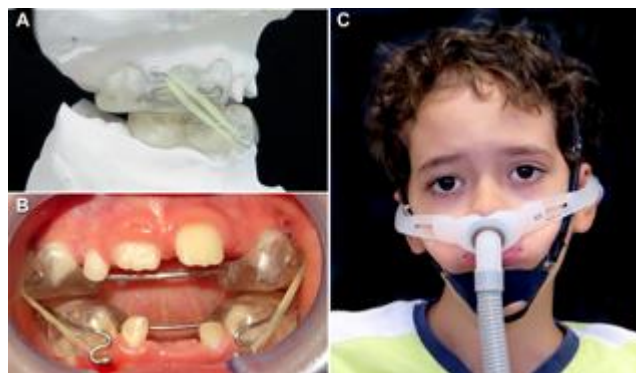
Co-funded by the
Erasmus+ Programme
of the European Union





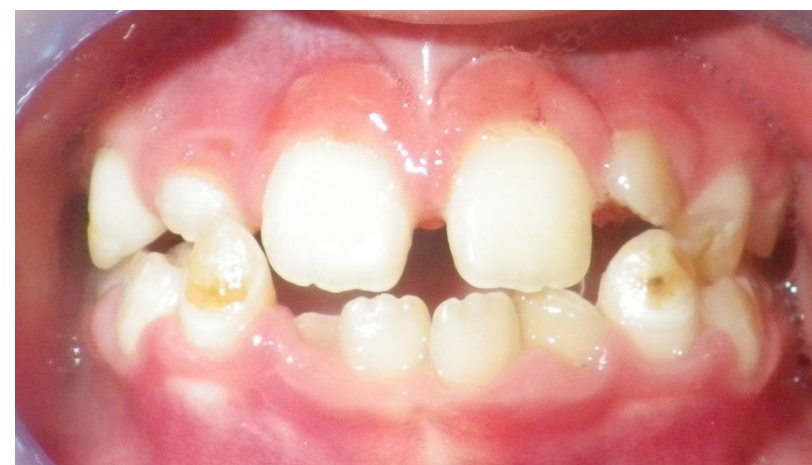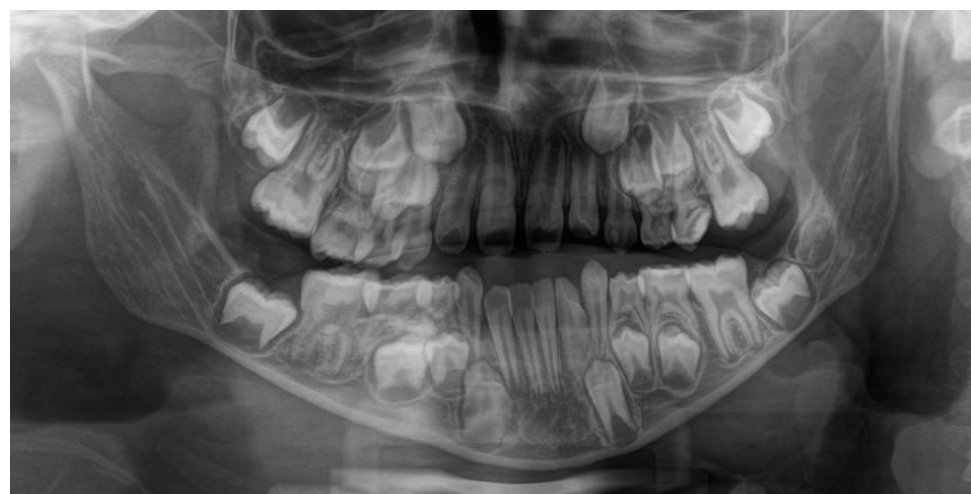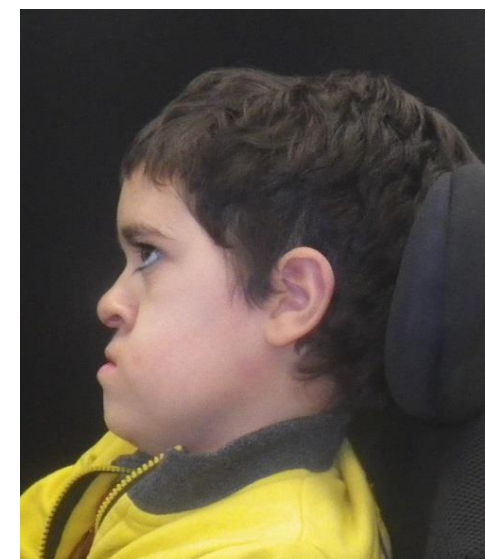
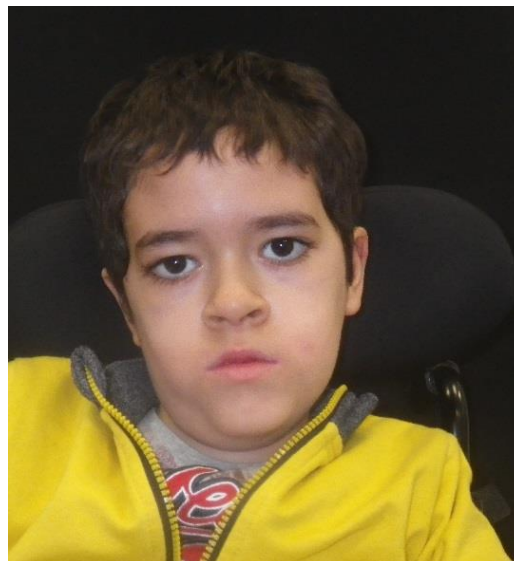
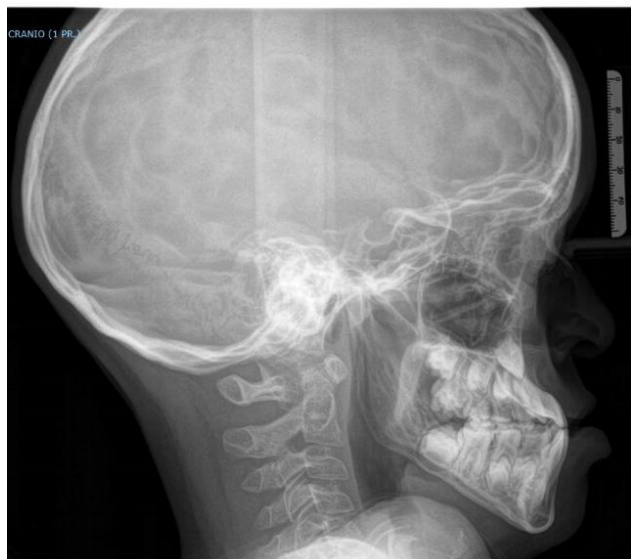N. J, 7 years old



Co-funded by the
Erasmus+ Programme
of the European Union



N. J, 9 years old



M. S., May 07th 2009



- **NON-CLASSIC INFANTILE POMPE DISEASE**

- Diagnosed at the age of 2 years by the Metabolic Pathology OU
- Chronic respiratory failure in therapy with nocturnal non-invasive ventilation (NIV)
- Hypertrophic cardiomyopathy
- Muscular hypotonia
- Enzyme replacement therapy with Myozyme
- ***Oral hygiene and prophylaxis***
- ***Dental treatment of decayed teeth***
- ***Rehabilitation therapy of facio-oral-deglutition functions including exercises to improve chewing and lip competence***
- ***Orthodontic treatment with Delaire double arch and Delaire facemask***

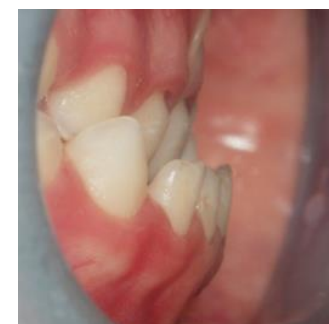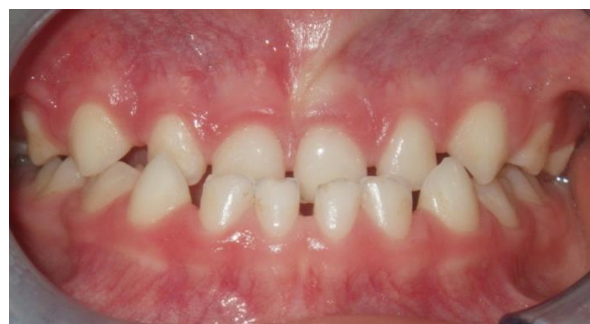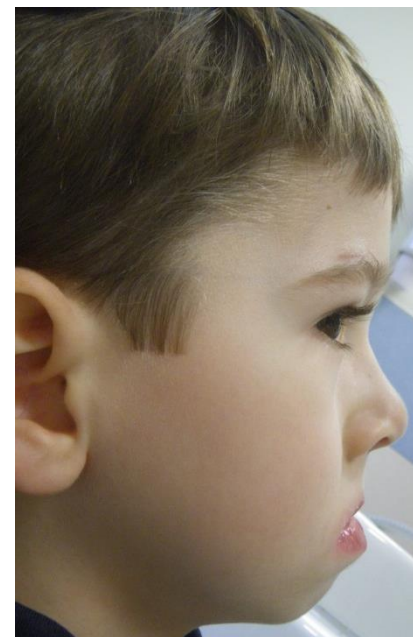
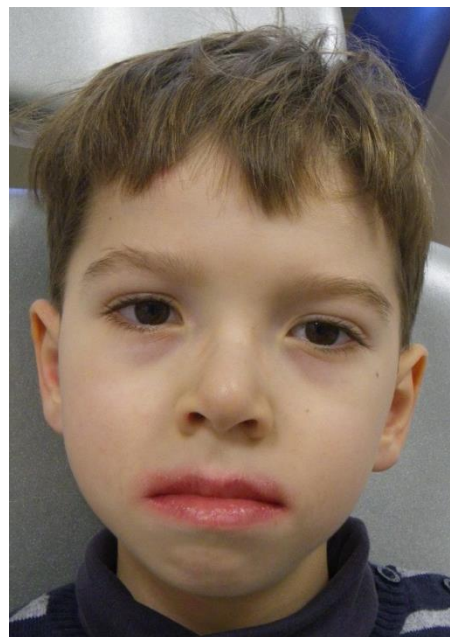


Co-funded by the
Erasmus+ Programme
of the European Union



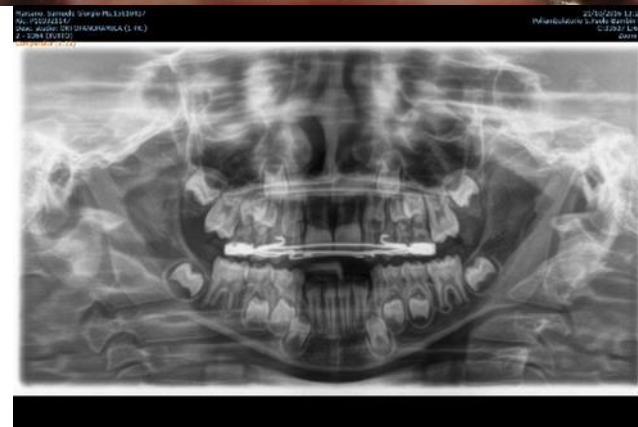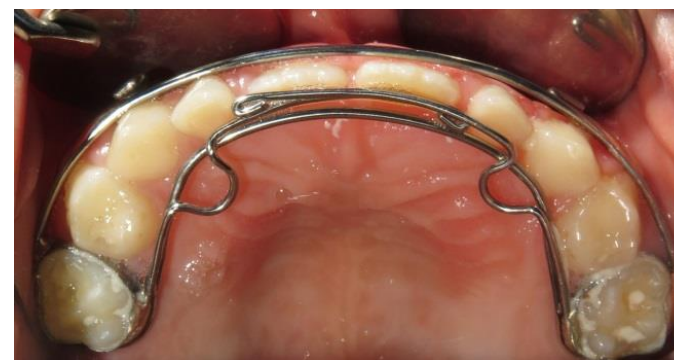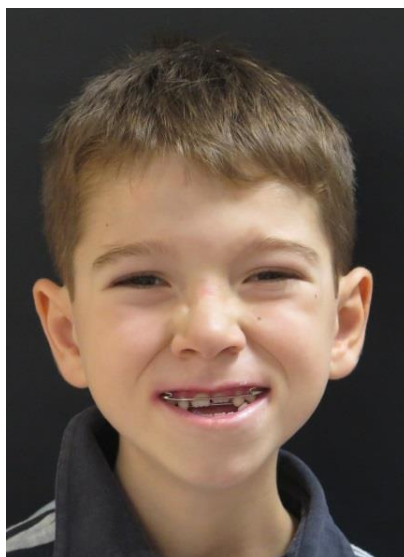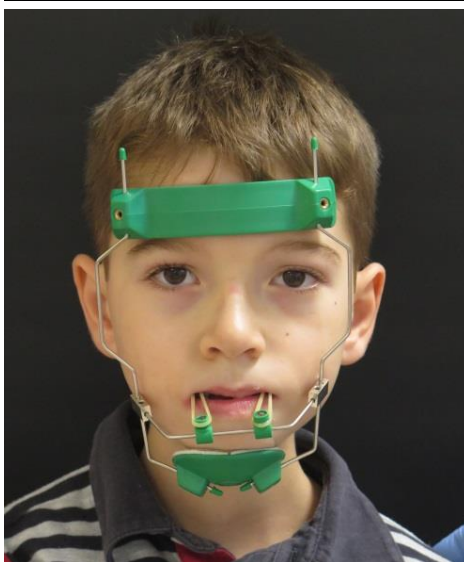


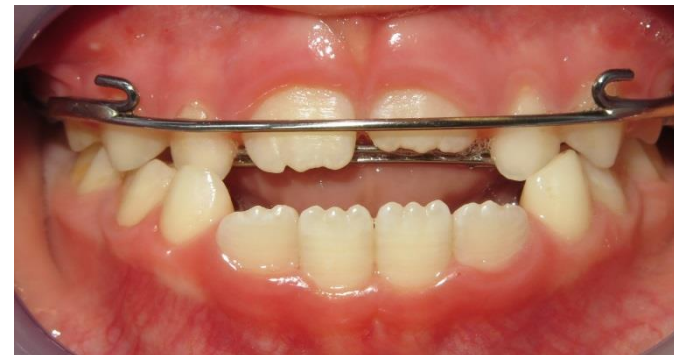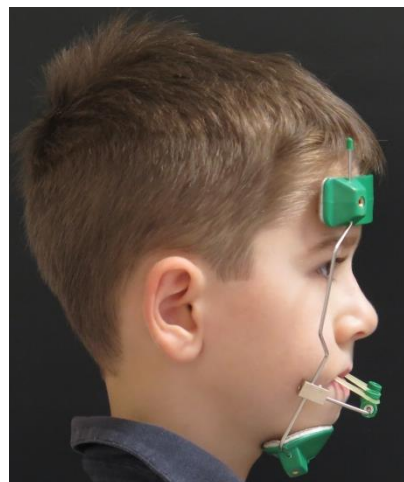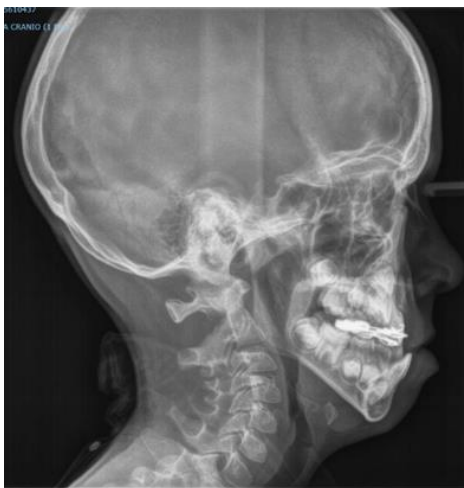M. S, 5 years old





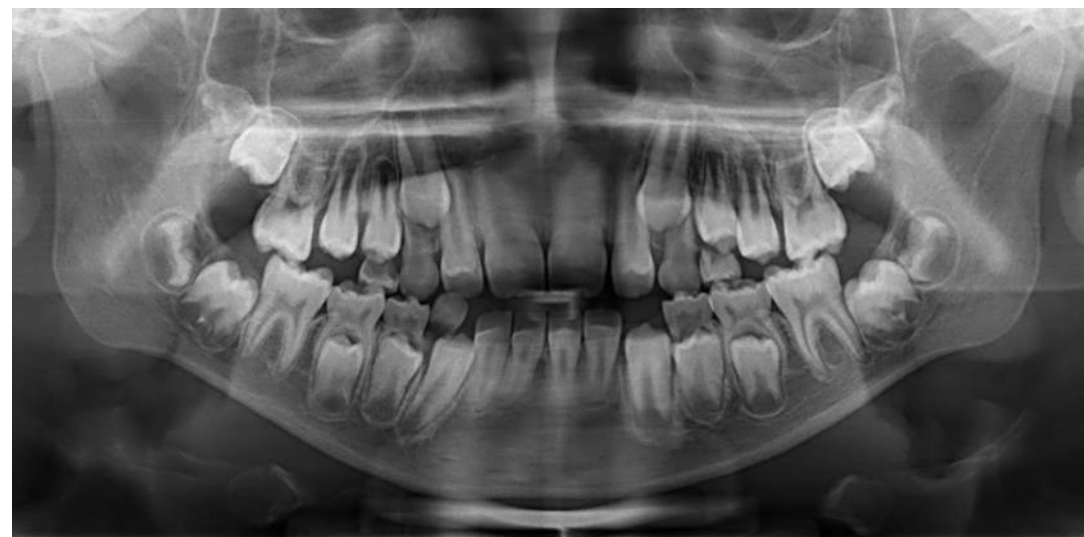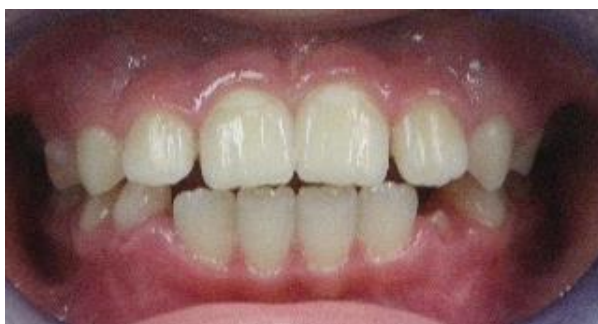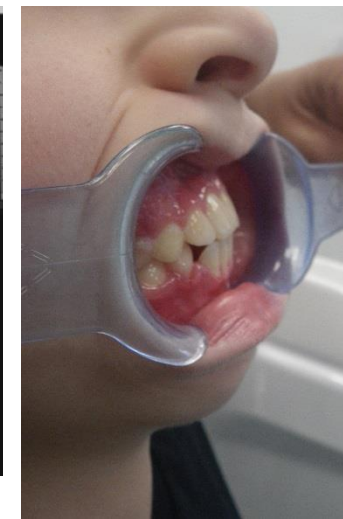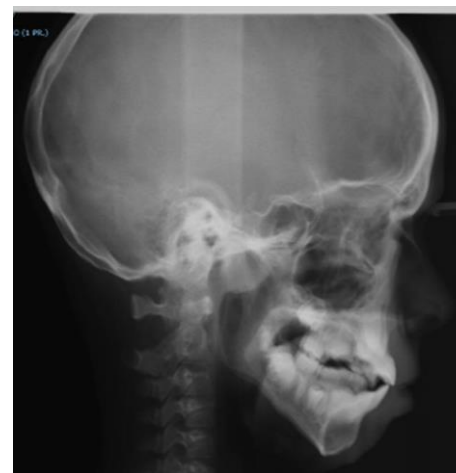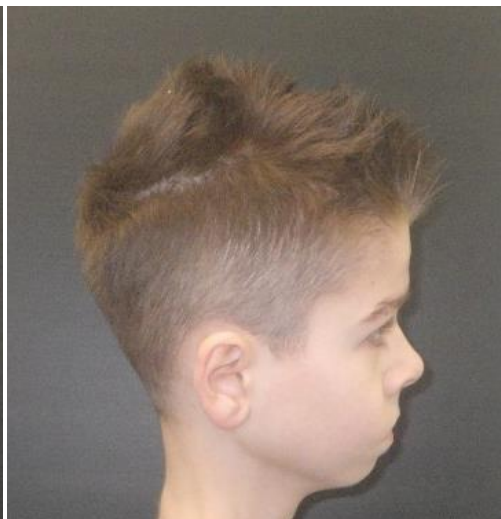M. S, 7 years old



Co-funded by the
Erasmus+ Programme
of the European Union



M. S, 10 years old





E. M., July 06th 2013

- **CLASSIC INFANTILE POMPE DISEASE**
- Diagnosed at the age of 3 months by the Metabolic Pathology OU
- Hypertrophic cardiomyopathy
- Muscular hypotonia
- Enzyme replacement therapy with Myozyme
- *Oral hygiene and prophylaxis*
- *Dental treatment of decayed teeth*
- *Rehabilitation therapy of facio-oral-deglutition functions including exercises to improve chewing and lip competence*

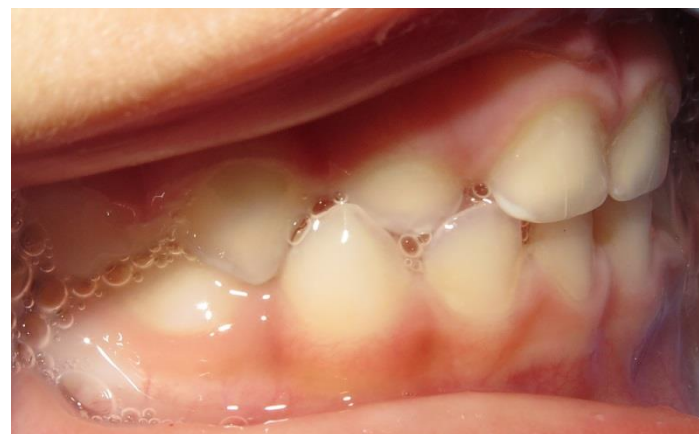
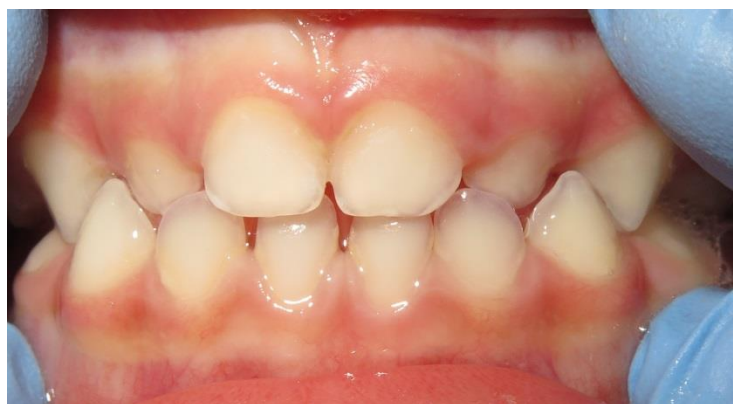
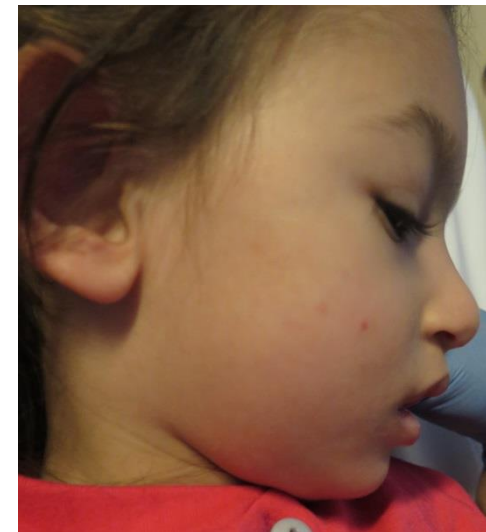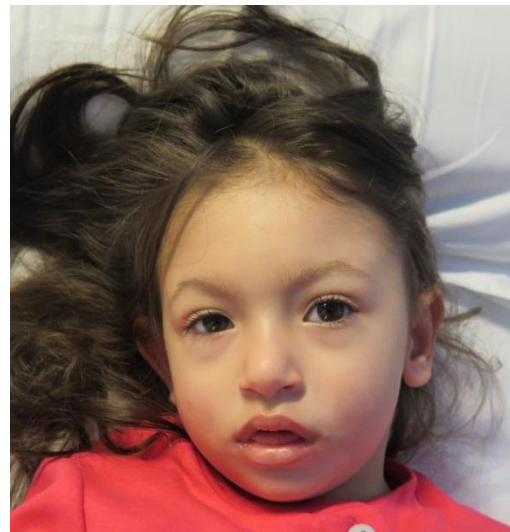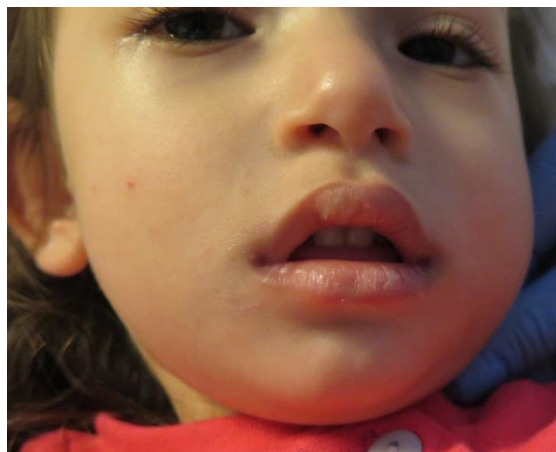Co-funded by the
Erasmus+ Programme
of the European Union





September 13th 2017, 4 years old

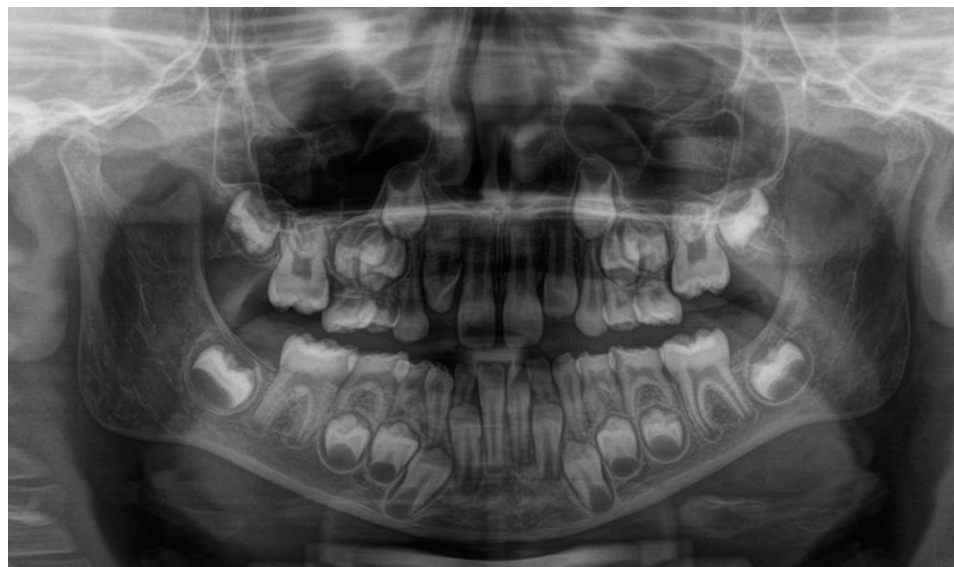
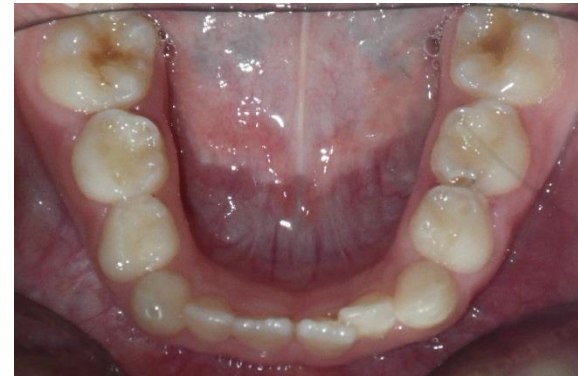
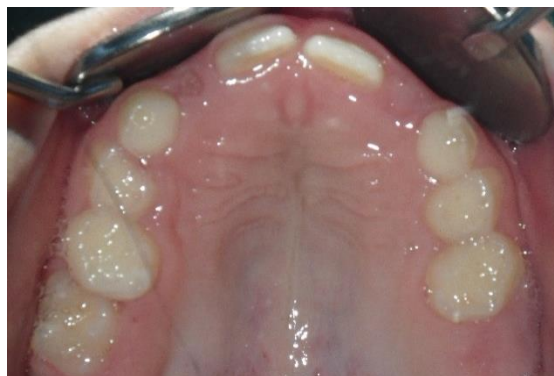Co-funded by the
Erasmus+ Programme
of the European Union





E. M, 6 years old



Co-funded by the
Erasmus+ Programme
of the European Union





E. M, 6 years old

