



the Child Dental Patient with

Neurofibromatosis

Clinical cases



Clinical case 1.

LD, male, age 8

Dr.Arina Vinereanu

General Dg: mild **NF Type 1**, with:

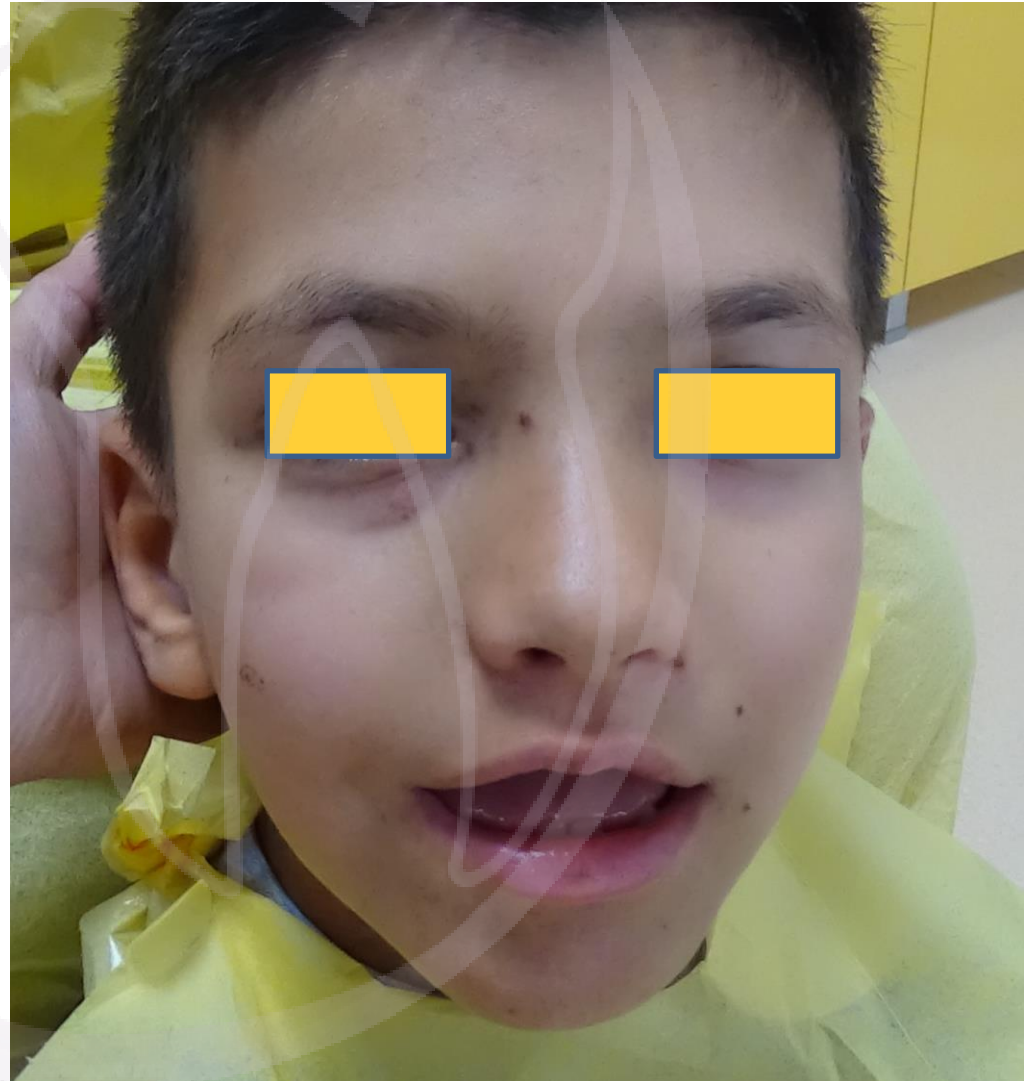
- moderate mental challenge
- behavioural disturbances
- typical skin spots
- facial dysmorphism
- right parietal bone mass
- atopic dermatitis

Anamnesis:

multiple extractions of carious primary teeth under GA at approximately age 3, motivated by young age and lack of cooperation for treatment

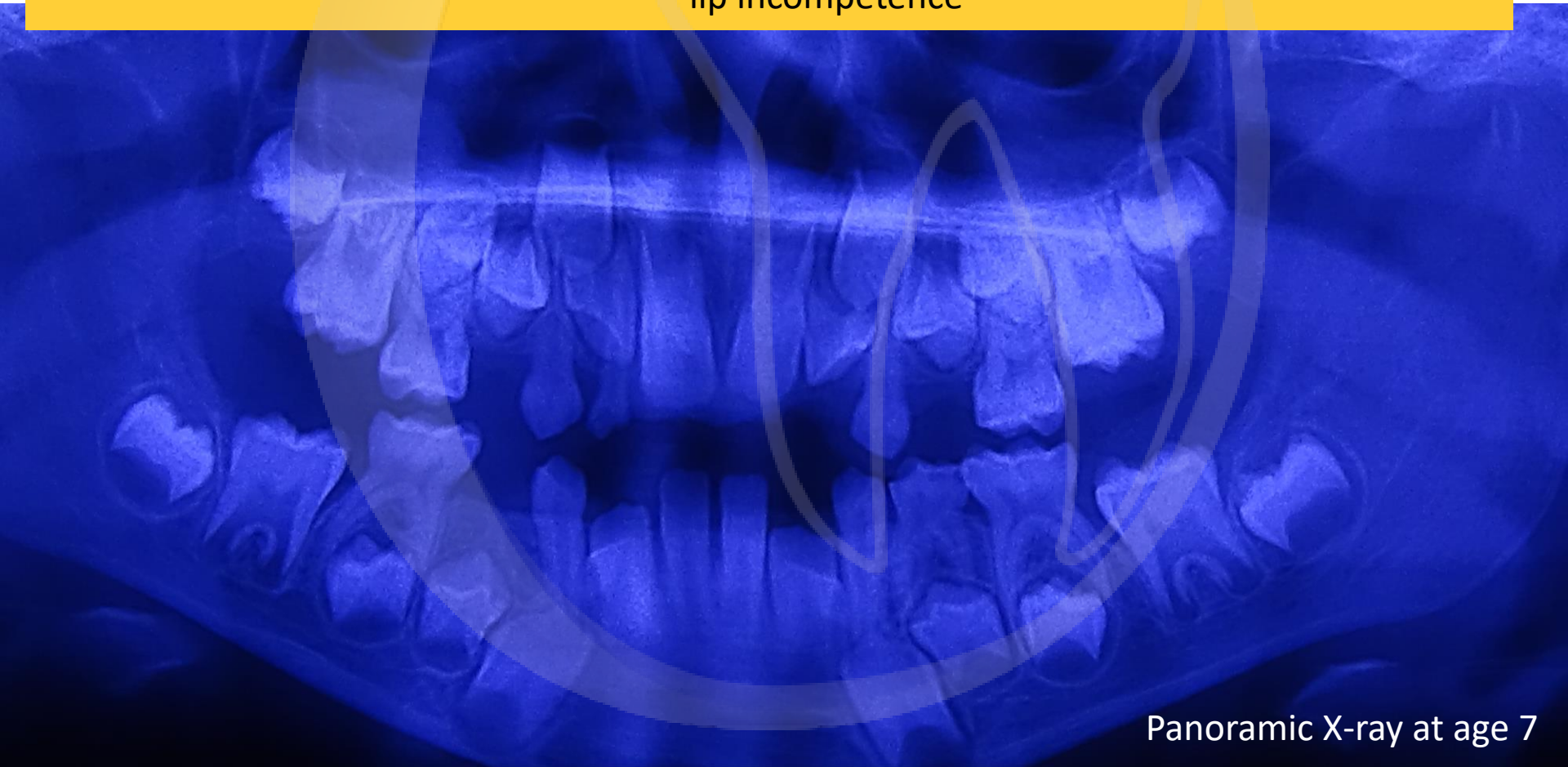
Reason for seeking treatment:

Family concern due to delayed eruption of upper central incisors

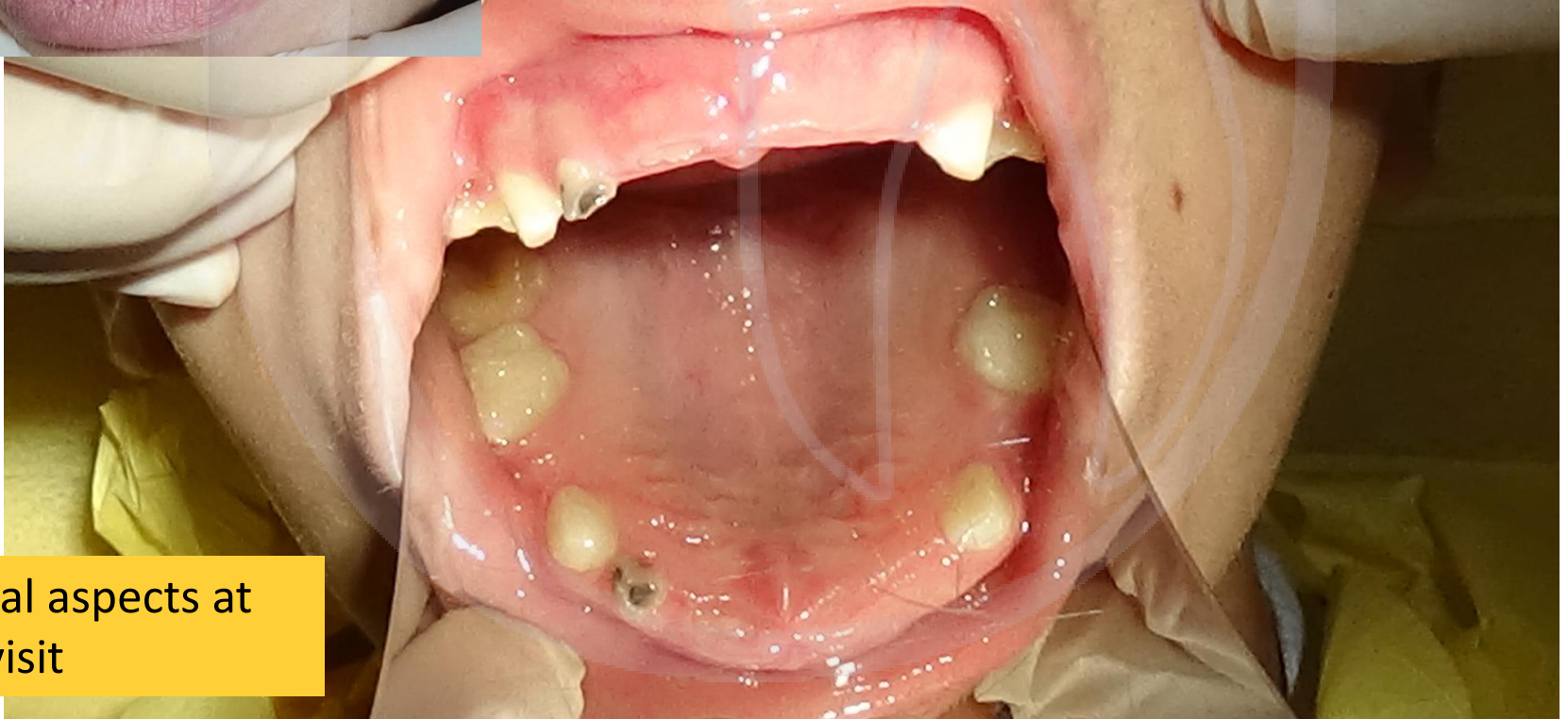
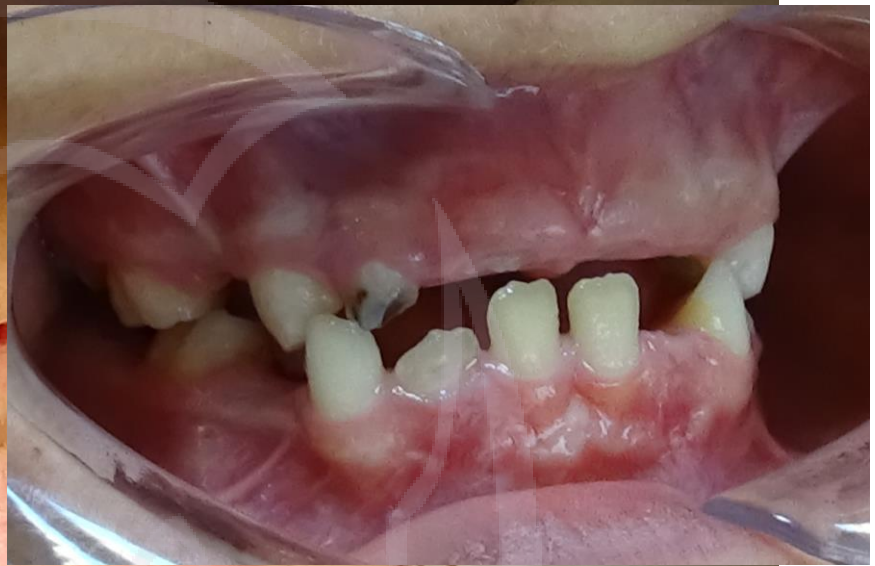
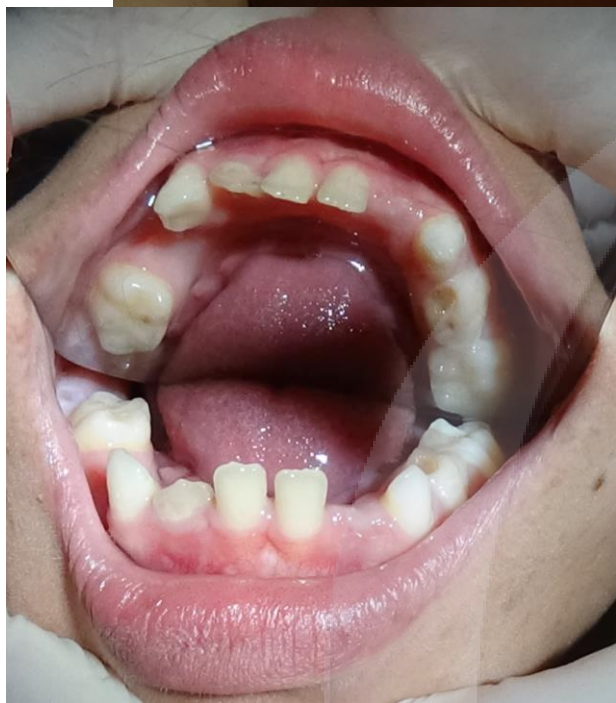
Dental dg. Mixed dentition, with:

- MIH lesions on erupting 16
- Extracted 54, 64, 84 with consequent mesial drifting of first permanent molars; caries on remaining deciduous teeth
- Mild gingivitis
- *Functional examination* revealed:
 - chronic oral breathing
 - lip incompetence



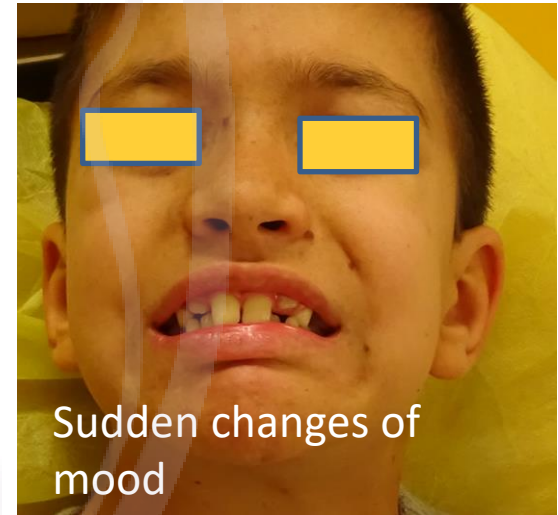
Panoramic X-ray at age 7



Clinical aspects at
first visit

Steps in *case management*:

1. Address family's concerns (delayed eruption) – easy, as 11 was already erupting
2. Progressive gain of patient's trust – non-invasive manoeuvres during first visit (brushing, photos), followed by sealants
3. Correct altered function (breathing) by recommending functional exercises
4. Orthodontic approach according to: clinical situation, family expectations, patient's likeliness to comply

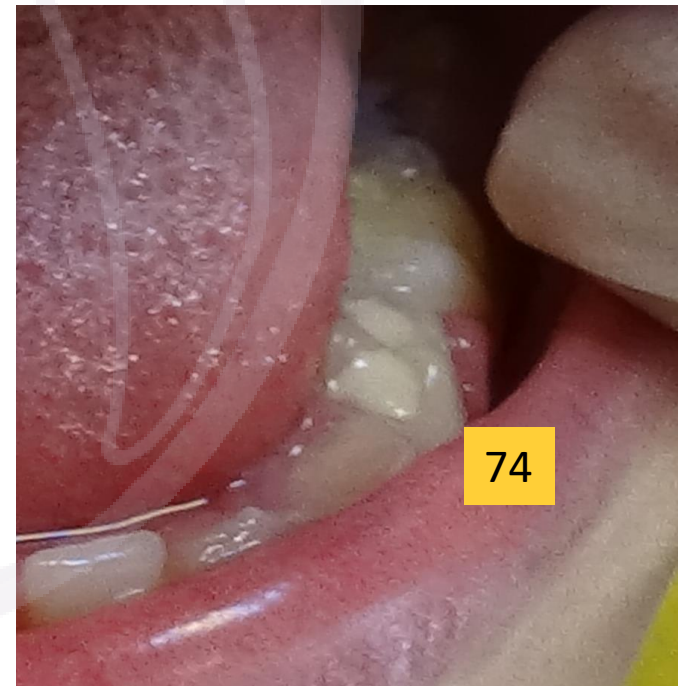
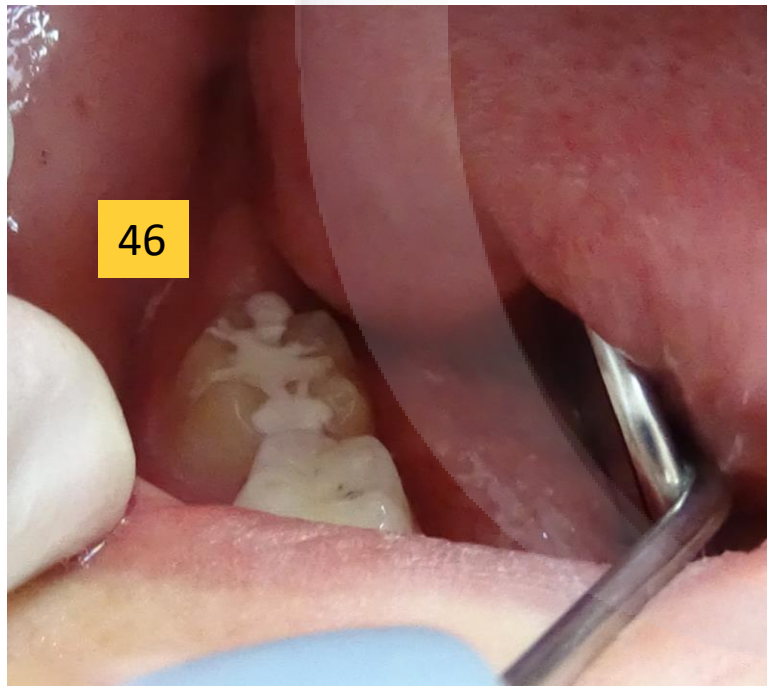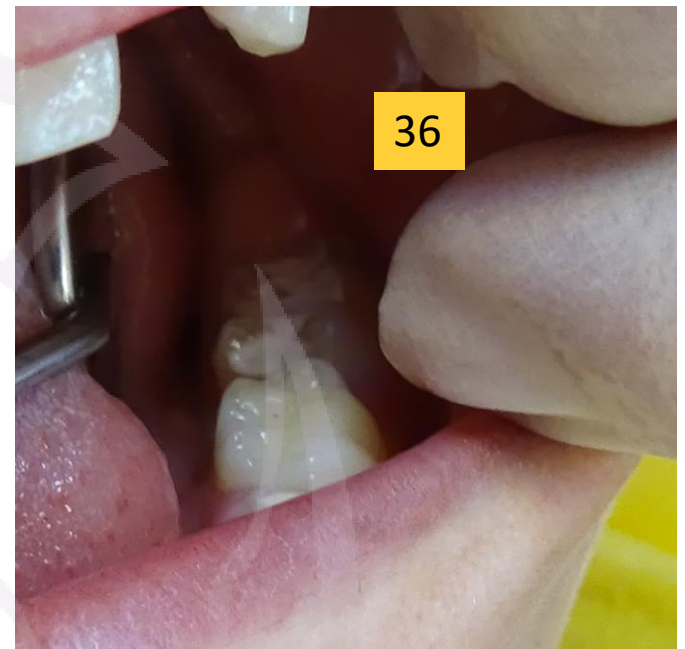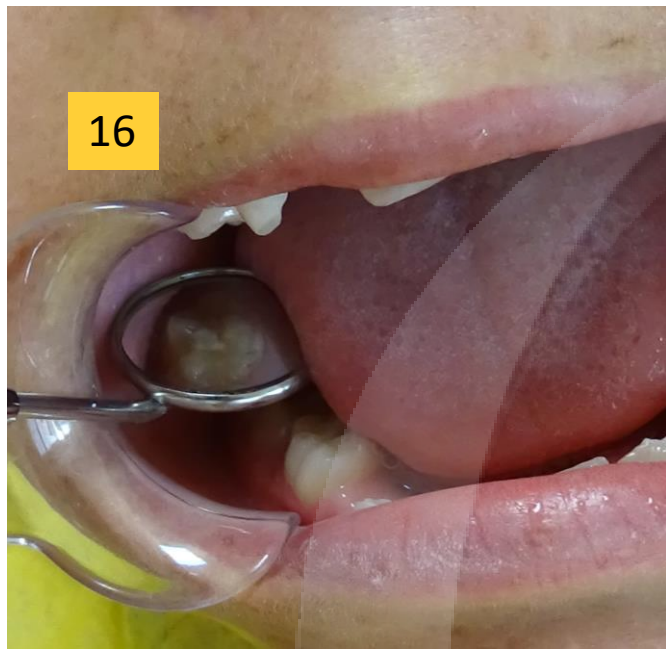


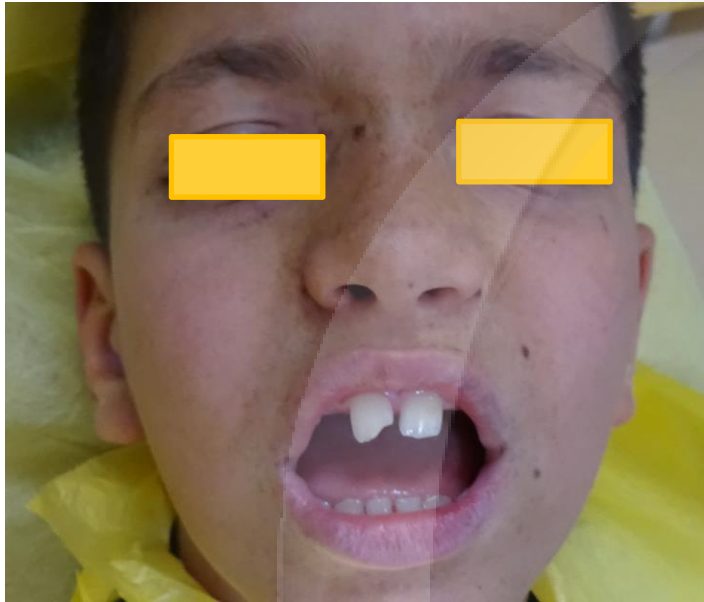Problems encountered:

- Geographic – patient from another county – longer time between successive appointments – risk of forgetting previously accepted steps
- Compliance – initially Frankl 2; progressed to Frankl 3-4; sudden changes of mood
- At second visit patient shows fractured of 11
- Mental challenge limits orthodontic approach

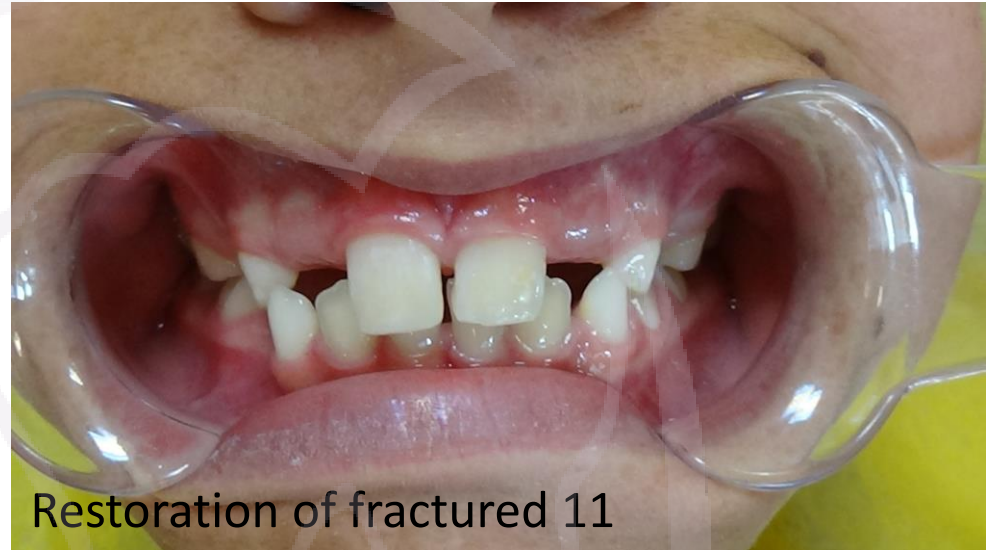Treatment (chronologic order):

- Professional cleaning; stimulate nasal breathing (exercises - home routine)
- Glass-ionomer (Fuji Triage) restoration on erupting 16 (with moderate MIH lesions)
- Glass-ionomer restorations on deciduous molars
- Glass-ionomer sealants on subsequently erupted 26, 36, 46
- Composite restoration on fractured 11 (enamel-dentin fracture, no pulp involvement)
- Start myofunctional therapy (LM removable device)

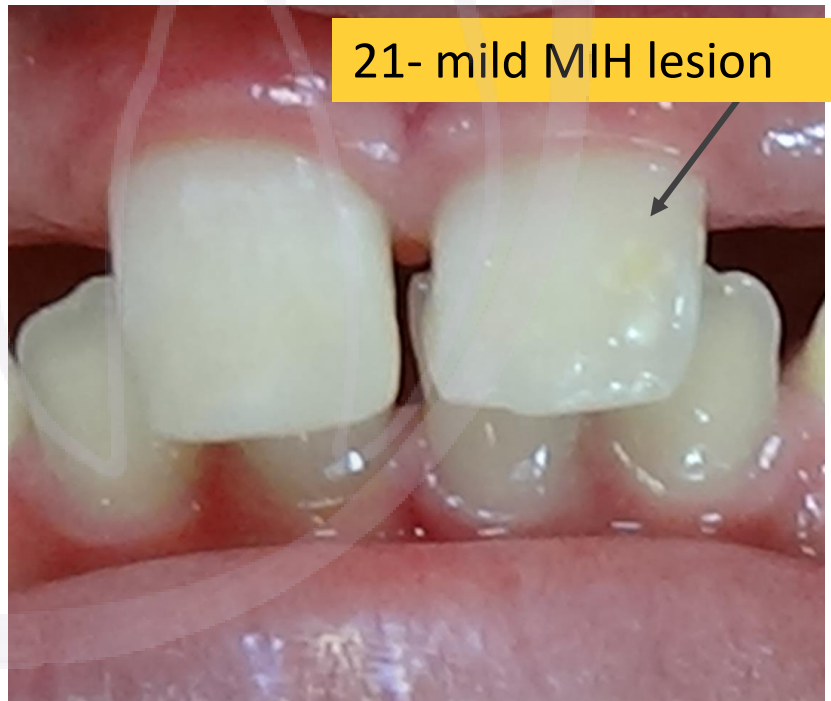
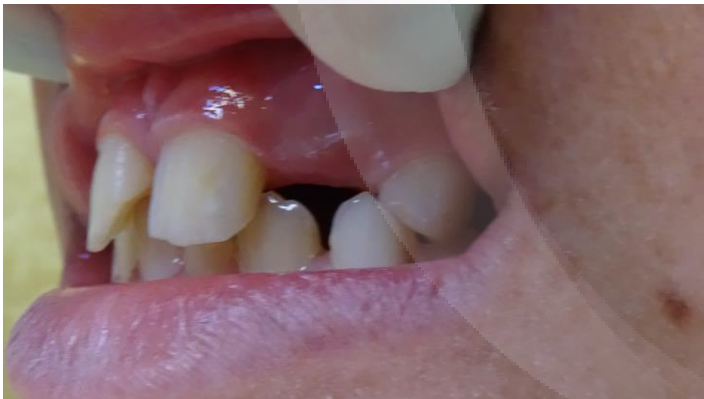


Fractured 11 – favoured by occlusion

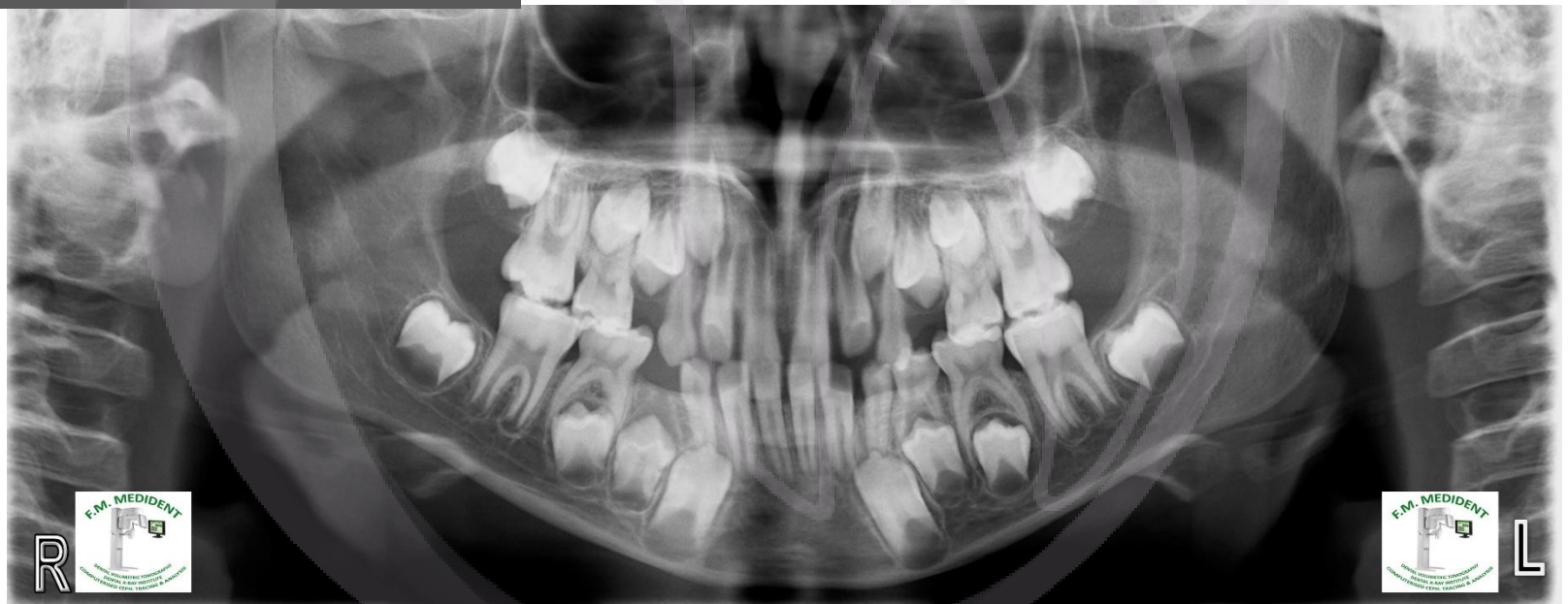

Restoration of fractured 11

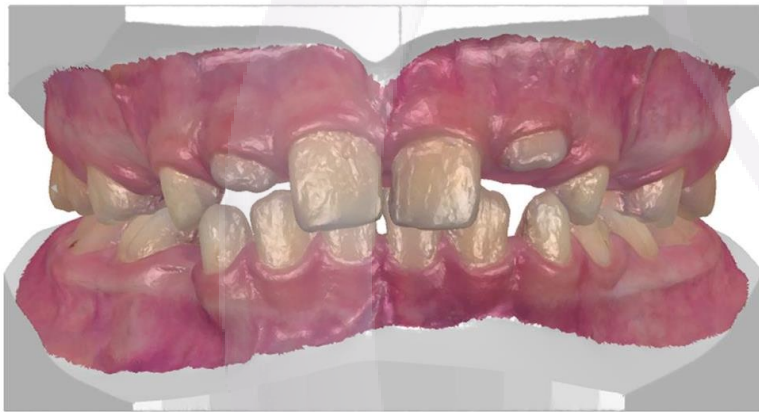

21- mild MIH lesion

Panoramic X-ray at age 9y 8m

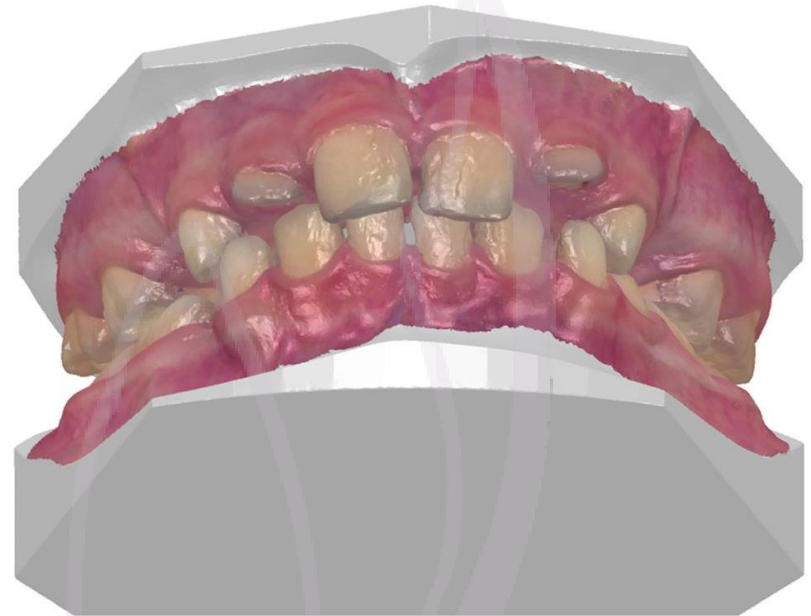


Clinical situation at age 9y 8m: malocclusion



R

L



R

L



Gradual introduction of MFT device – age 9y 11m