



*the Child Dental Patient with*

---

# Primary Failure of Eruption



## Clinical case 1. : isolated form

LA, male

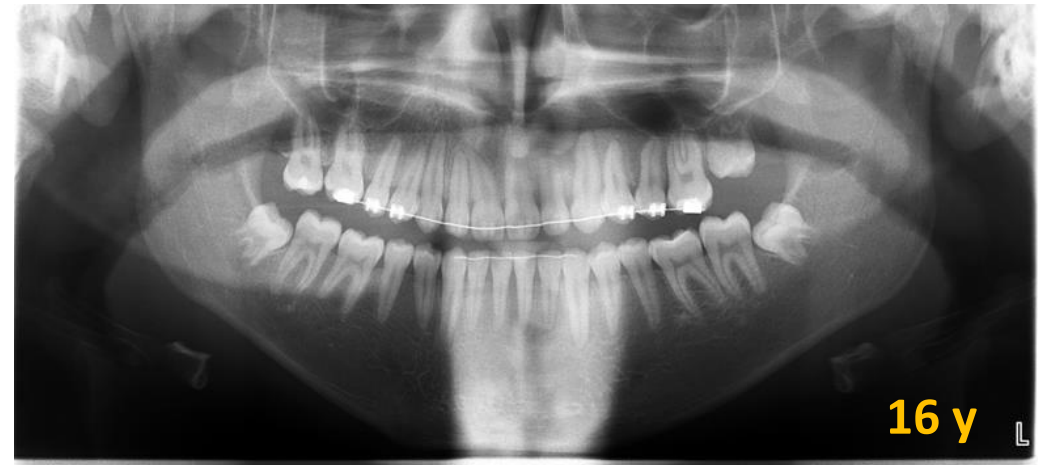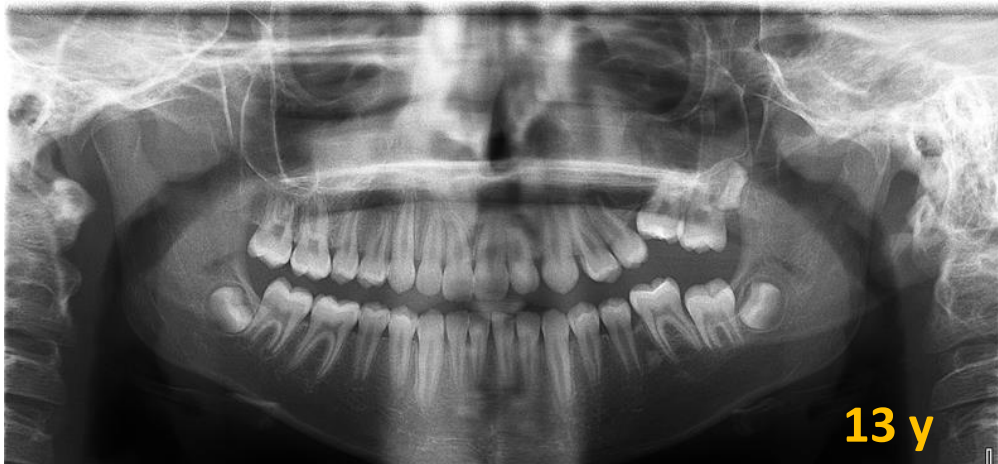General dg: /

Dental dg and treatment

- 26 ankylosis => alveolectomy and extraction
- 27: spontaneous evolution
- orthodontic alignment

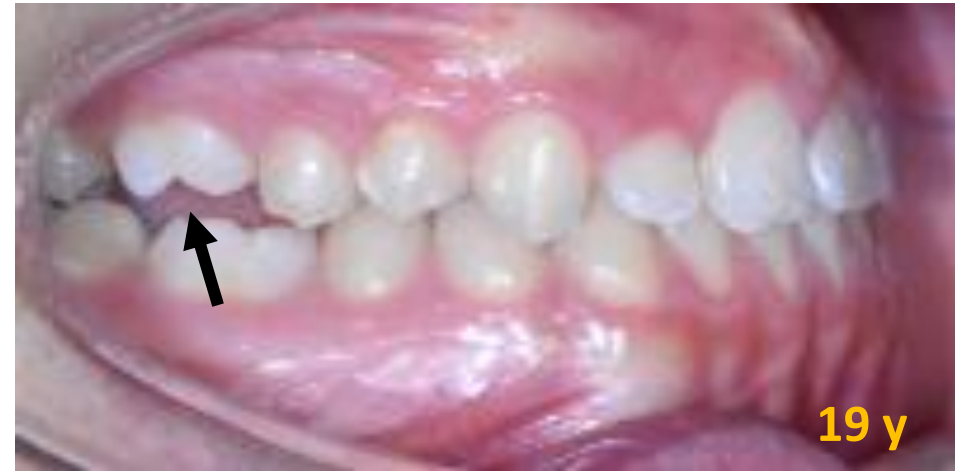Family history: mother affected

Genetic dg: mutation of *PTHR1* gene



Control visit

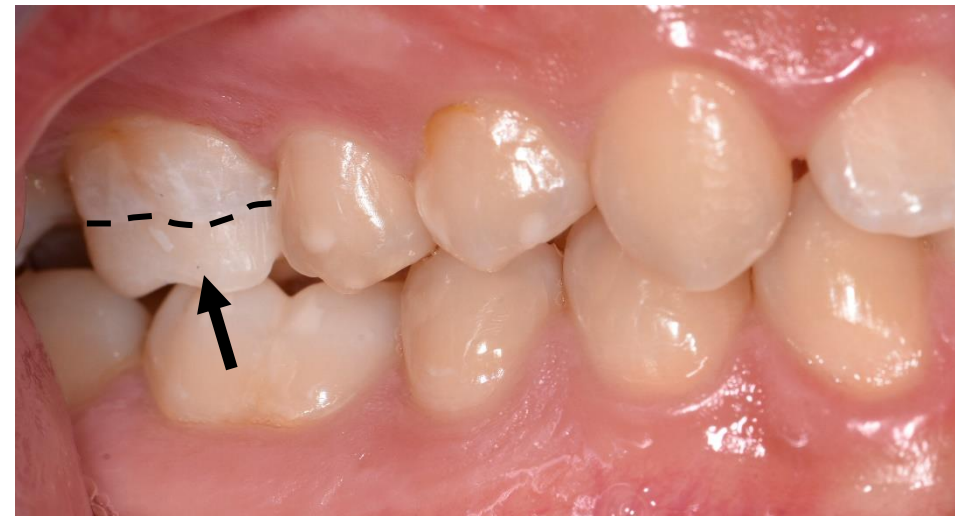
- 16: infraclulsion and ankylosis



Therapeutic decision:

Bonding of a ceramic overlay using CAD-CAM

Monitoring of the possible appearance of new ankyloses or internal resorptions



## Clinical case 2. : isolated form

IS, female, 5y8m

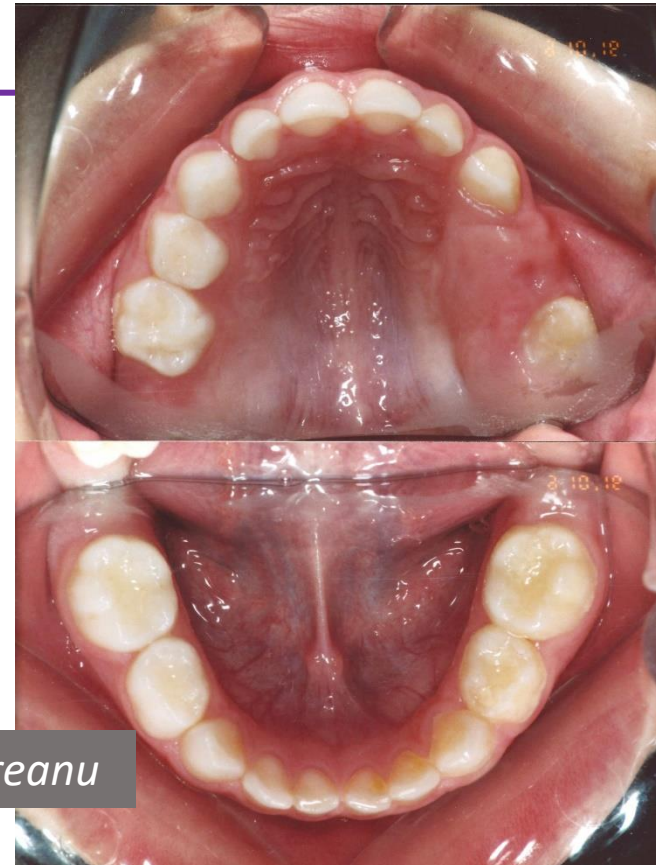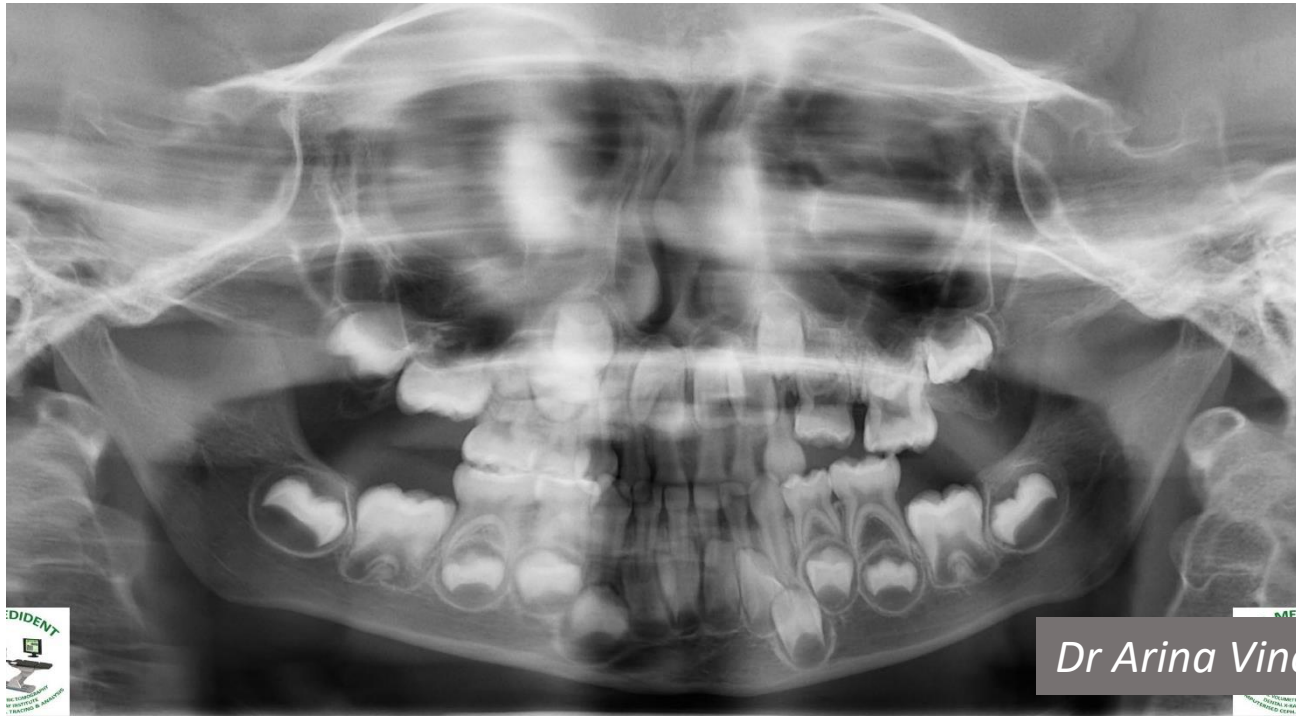General dg: -

Dental dg : deciduous dentition, with

- 64 unerupted
- 65 incomplete eruption
- 26 delayed intraosseous development
- crowding

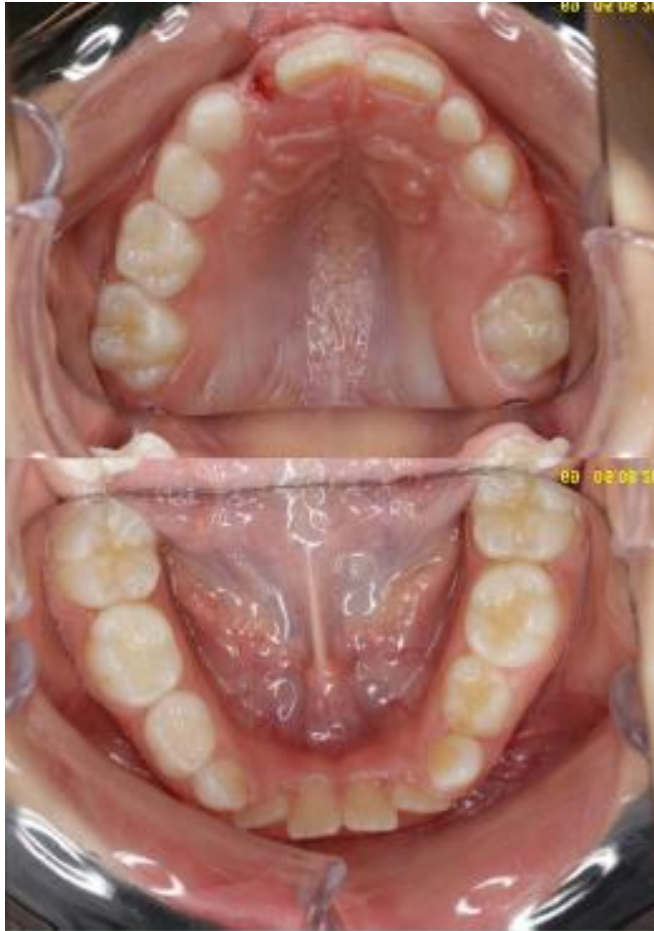Family history: irrelevant

Genetic dg: -

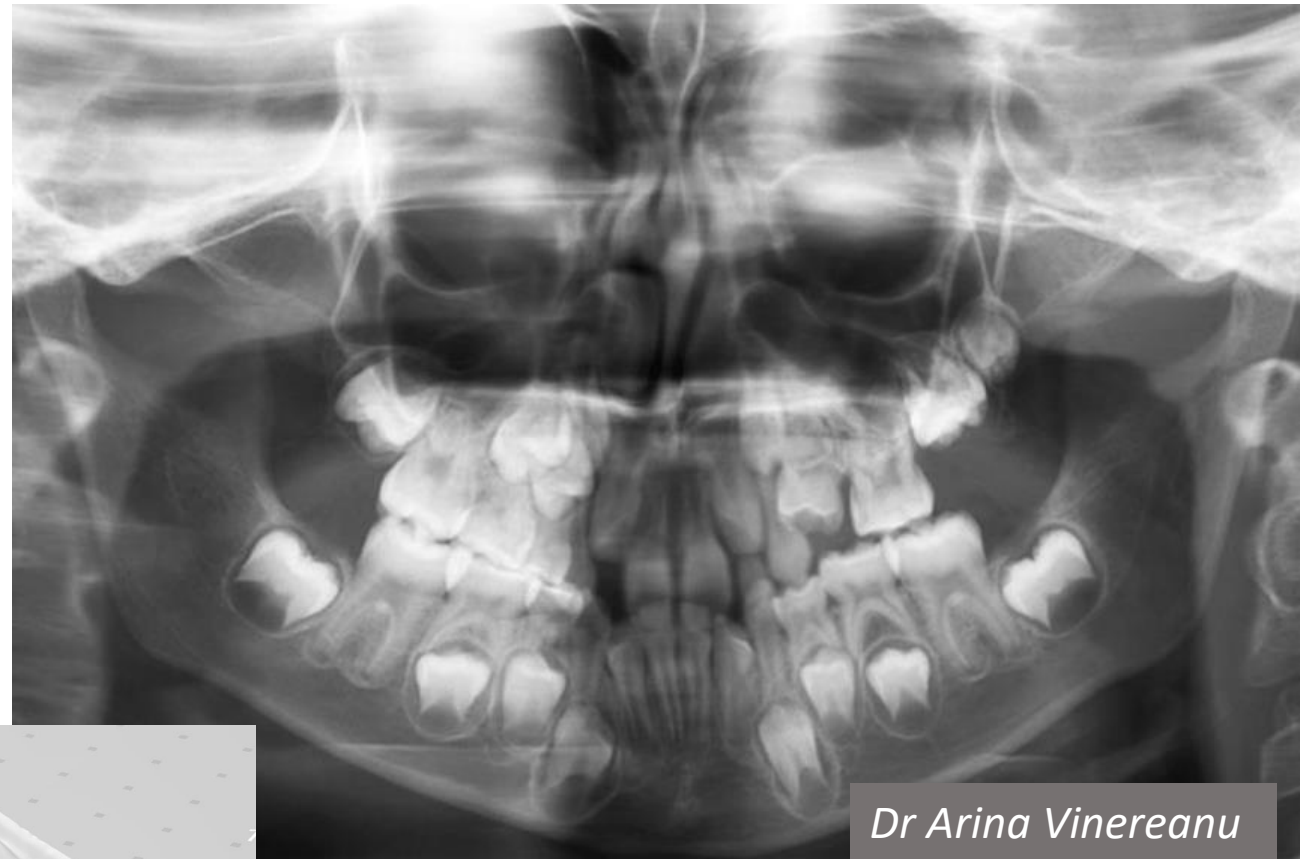

Dr Arina Vinereanu

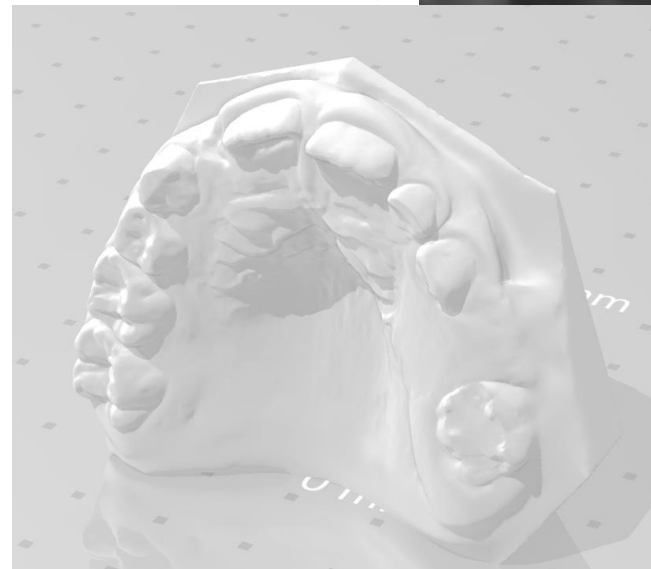




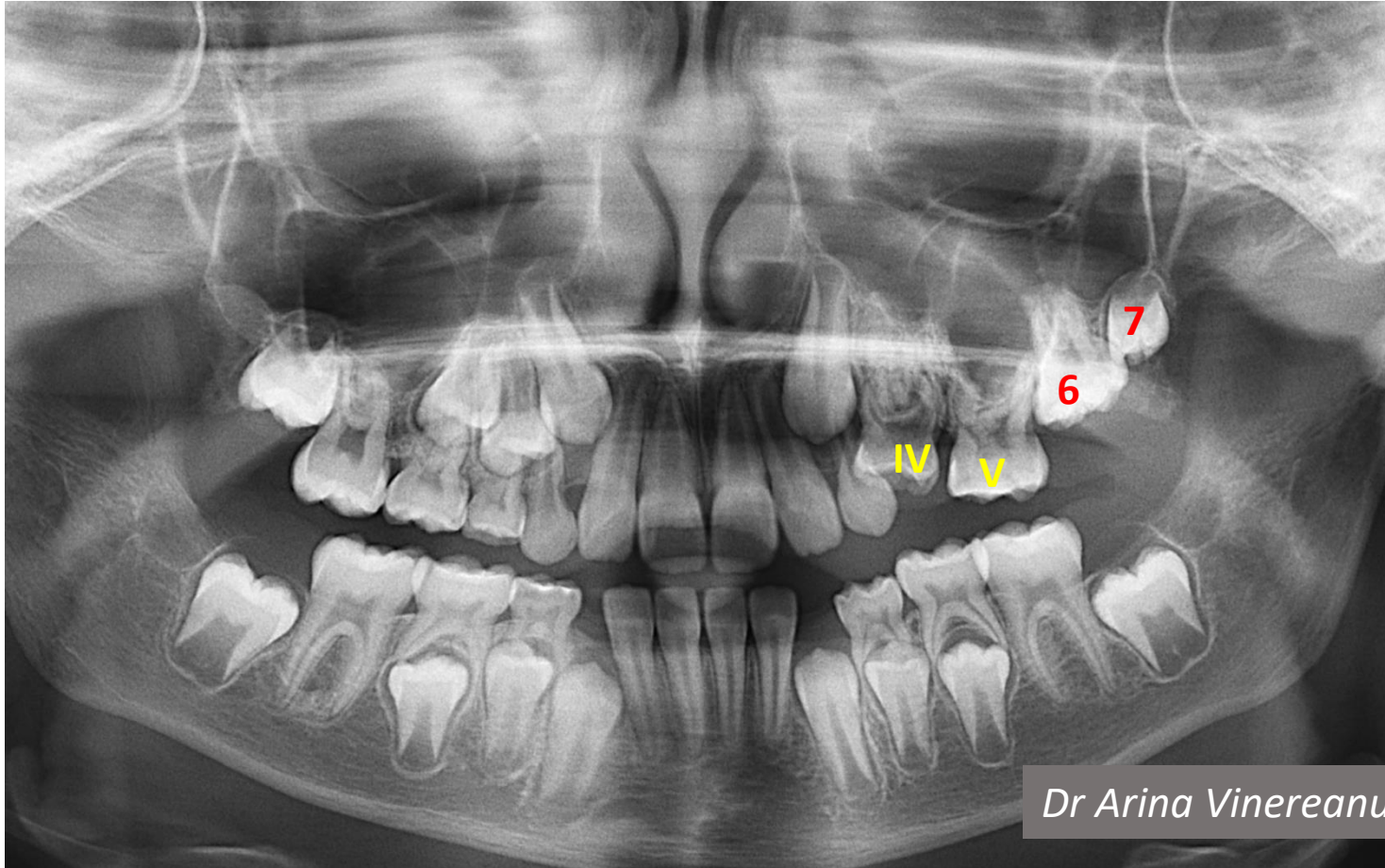
age 8y8m




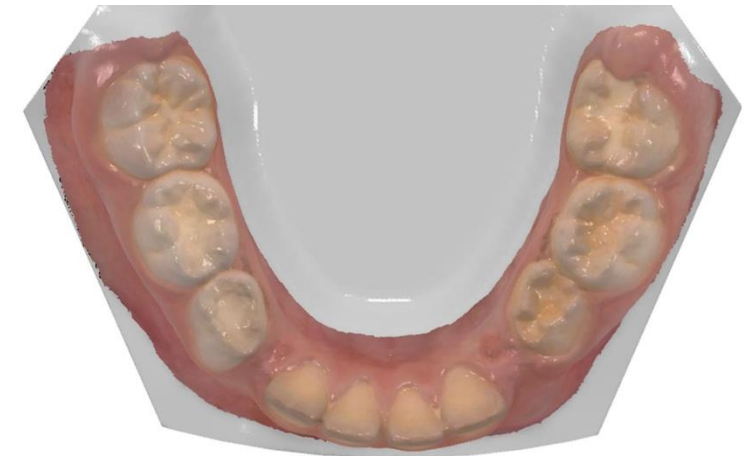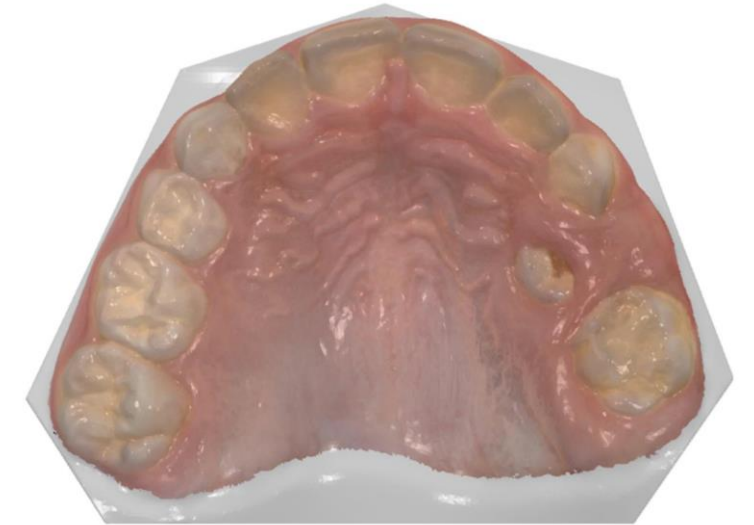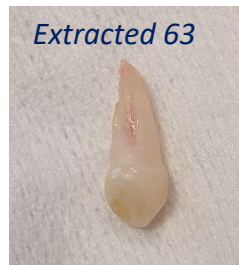Dr Arina Vinereanu



age 10 y 9 m



At this stage, the plan is: extraction of 63  in order to facilitate full eruption of 64 (impacted), followed by extraction of 64; further decisions to be taken according to the evolution of the case



*Case under follow-up*